

A Longitudinal Analysis of Pre- and Post-Operative Dymorphology in Metopic Craniosynostosis

Justin W. Beiriger, MD, MSc¹, Wenzheng Tao, MS², Zhazira Irgebay, MD¹ ,
 John Smetona, MD¹, Lucas Dvoracek, MD¹, Nicolás M. Kass, BA¹ ,
 Angel Dixon, BA¹, Casey Zhang, BA¹, Meeti Mehta, BS¹,
 Ross Whitaker, PhD², and Jesse A. Goldstein, MD¹ 

The Cleft Palate Craniofacial Journal
 1-7

© 2024, American Cleft Palate
 Craniofacial Association
 Article reuse guidelines:
sagepub.com/journals-permissions
 DOI: 10.1177/10556656241237605
journals.sagepub.com/home/cpc



Abstract

Objective: The purpose of this study is to objectively quantify the degree of overcorrection in our current practice and to evaluate longitudinal morphological changes using CranioRate™, a novel machine learning skull morphology assessment tool.

Design: Retrospective cohort study across multiple time points.

Setting: Tertiary care children's hospital.

Patients: Patients with preoperative and postoperative CT scans who underwent fronto-orbital advancement (FOA) for metopic craniosynostosis.

Main Outcome Measures: We evaluated preoperative, postoperative, and two-year follow-up skull morphology using CranioRate™ to generate a Metopic Severity Score (MSS), a measure of degree of metopic dysmorphology, and Cranial Morphology Deviation (CMD) score, a measure of deviation from normal skull morphology.

Results: Fifty-five patients were included, average age at surgery was 1.3 years. Sixteen patients underwent follow-up CT imaging at an average of 3.1 years. Preoperative MSS was 6.3 ± 2.5 (CMD 199.0 ± 39.1), immediate postoperative MSS was -2.0 ± 1.9 (CMD 208.0 ± 27.1), and longitudinal MSS was 1.3 ± 1.1 (CMD 179.8 ± 28.1). MSS approached normal at two-year follow-up (defined as MSS = 0). There was a significant relationship between preoperative MSS and follow-up MSS ($R^2 = 0.70$).

Conclusions: MSS quantifies overcorrection and normalization of head shape, as patients with negative values were less "metopic" than normal postoperatively and approached 0 at 2-year follow-up. CMD worsened postoperatively due to postoperative bony changes associated with surgical displacements following FOA. All patients had similar postoperative metopic dysmorphology, with no significant association with preoperative severity. More severe patients had worse longitudinal dysmorphology, reinforcing that regression to the metopic shape is a postoperative risk which increases with preoperative severity.

Keywords

metopic, craniosynostosis, overcorrection, machine learning, morphology, outcome

Introduction

Metopic craniosynostosis is surgically managed for one or both of two indications: to treat/prevent neurologic sequelae of increased intracranial pressure (ICP) and/or to aesthetically correct head shape malformation. Surgical goals include improvement of forehead shape, correction of hypotelorism, and expansion of the anterior cranial fossa to generate space for the rapidly growing brain.¹ Fronto-orbital advancement (FOA) is often the procedure of choice. It involves reconstructing and repositioning the frontal bones and the supraorbital bandeau to widen forehead, correct the frontozygomatic restriction, and improve the contour of the skull.² Aesthetic outcomes following FOA are challenging to objectively quantify.³

Long-term outcomes following FOA are influenced by the timing of intervention, pre-operative head shape, surgical technique, and the subjective assessment of the surgeon, resulting in a wide variability in reported outcomes.³ Despite quantified

¹ Department of Plastic Surgery, University of Pittsburgh Medical Center, Pittsburgh, PA, USA

² School of Computing, Scientific Computing and Imaging Institute, University of Utah, Salt Lake City, UT, USA

Corresponding Author:

Jesse A. Goldstein, Associate Professor, Craniofacial Fellowship Director, Department of Plastic Surgery, Children's Hospital of Pittsburgh, University of Pittsburgh Medical Center, Pittsburgh, PA, USA.

Email: Jesse.goldstein@chp.edu

improvements in head shape in the immediate post-operative period, abnormal cranial morphology may still develop postoperatively.^{4,5} This potential result has led many to adopt an overcorrection technique to compensate for anticipated growth restriction and/or relapse.⁶ However, the extent of overcorrection is challenging to quantify, as is its influence on the degree of longitudinal skull dysmorphology. As a result, achieving a normal or non-stigmatizing head shape is difficult to confirm objectively, especially in the early postoperative period when there is overt overcorrection of the anterior cranium.⁷

Longitudinal follow-up is critical to monitor changes in head shape postoperatively. Previous studies have utilized cephalometry, such as the bifrontal angle, to diagnose and classify phenotypic severity of metopic synostosis.^{8,9} However, these measurements are reductive and fail to account for holistic three-dimensional head shape.¹⁰ In addition, the Whitaker Classification is a standard subjective measure to evaluate severity in craniosynostosis, qualitatively scored from 1 to 4.¹¹ While the Whitaker Classification is easy to use and widely accepted, it is limited due to its subjectivity and low interrater reliability.¹² The purpose of this study was to apply a validated machine learning quantification tool, CranioRateTM,¹³ to objectively evaluate immediate and longitudinal postoperative results in patients with metopic craniosynostosis with the goal of quantifying the degree of overcorrection and of evaluating the relationship between degree of overcorrection and longitudinal morphology.

Methods

Patient Selection and Variable Selection

Following institutional review board approval, a retrospective cohort study of patients with isolated, non-syndromic metopic craniosynostosis who underwent FOA by a member of the surgical team between 2007–2020 at a tertiary children's hospital was performed. All patients in this study underwent FOA using the surgical technique previously described.¹⁴ Exclusion criteria included patients with multi-suture involvement and syndromic diagnoses. Patients were only included if they underwent preoperative and immediate postoperative CT scans, as was the institutional protocol for the duration of this study. Data collected included patient demographics, preoperative and postoperative computed tomographic (CT) imaging and associated clinical data. CT imaging scans were obtained at three time points for each patient: preoperatively, postoperatively, and at two-year follow-up in accordance with standard-of-care in our center. Our follow-up imaging protocol changed in 2018, however, and patients who underwent FOA after this time received a 3D photograph instead of CT. These photographs were not able to be used in our analysis.

Application of CranioRateTM Algorithm

Each CT image was analyzed utilizing the CranioRateTM machine learning (ML) algorithms. Two validated metrics were generated for each imaging sample: Metopic Severity

Score (MSS) and Cranial Morphology Deviation (CMD), as previously described in the literature.^{13,15-19} MSS is specific to metopic synostosis and quantifies the severity of deviation from normal head shape in the metopic direction; in other words, MSS quantifies the “metopic-ness” of a patient, where the score is scaled so that 0 represents an average normal control and 10 represents the most severely metopic patient in our dataset. An MSS of less than 0 corresponds to a patient that is less metopic in shape than a normal patient. CMD, on the other hand, is a non-specific measure of head shape that simply quantifies deviation from normal in any direction, and ranges from 60 to 290. In comparison, CMD would be high in a patient with severe metopic craniosynostosis *as well as* any other cranial dysmorphology, including those resulting from surgery, while MSS will only be high in patients with metopic craniosynostosis.¹⁷ In addition, CranioRateTM provides percentiles with each score, indicating the relative severity of each scan compared to a large series of greater than 250 patients with metopic craniosynostosis.

Statistical Analysis

Descriptive statistics were presented for each severity metric. In addition, linear regression analyses were performed to examine the relationships between preoperative, immediate postoperative, and follow-up severity scores. Statistical analyses were performed using Microsoft Excel (Redmond, WA) and Stata (College Station, TX). P-values < 0.05 were determined to be significant.

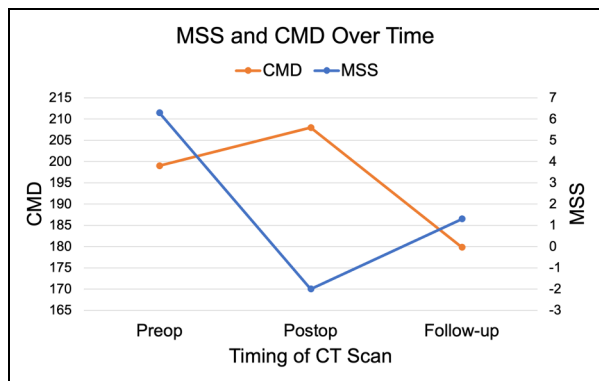
Results

Fifty-five patients who underwent FOA with pre- and postoperative CT scans were included in this study. Patients underwent FOA at an average age of 1.31 ± 0.51 years. Of these patients, 35 underwent surgery prior to our follow-up CT protocol change in 2018, 19 patients were either lost to follow-up or declined a third scan, resulting in 16 patients with two-year follow-up data at an average of 1.82 ± 0.70 years postoperatively. Preoperatively, the average MSS was 6.3 ± 2.5 (54th percentile) and the average CMD was 199.0 ± 39.1 (51st percentile). Immediately postoperatively, the average MSS was -2.0 ± 1.9 (1st percentile) and the average CMD was 208.0 ± 27.1 (58th percentile). At two-year follow-up, the average MSS was 1.3 ± 1.1 (9th percentile) and the average CMD was 179.8 ± 28.1 (37th percentile). These data are summarized in Table 1 and Figure 1. From prior analysis, the average control patient has an MSS of 0.0 ± 1.0 and a CMD of 85.2 ± 19.2 , while the average patient with metopic craniosynostosis has an average MSS of 4.9 ± 2.3 and a CMD of 189.9 ± 43.4 .

Example images of preoperative, immediate postoperative, and two-year postoperative CT scans are provided in Figure 2 and Figure 3. Figure 2 shows a patient with a relatively mild preoperative MSS of 3.0 (20th percentile), overcorrected to an MSS of -3.5 , and an acceptable two-year MSS of 0.5 (3rd percentile). Figure 3 shows a patient with a relatively

Table 1. CranioRate™ Results.

	N	MSS	MSS Percentile	CMD	CMD Percentile
Preop	55	6.3 ± 2.5	0.54 ± 0.27	199.0 ± 39.1	0.51 ± 0.27
Immediate Postop	55	-2.0 ± 1.9	0.01 ± 0.04	208.0 ± 27.1	0.58 ± 0.22
Two-year Follow-up	16	1.3 ± 1.1	0.09 ± 0.06	179.8 ± 28.1	0.37 ± 0.21

**Figure 1.** Trends of metopic severity scores MSS and CMD from preoperative, immediate postoperative, and two-year follow-up postoperative results.

severe preoperative MSS of 9.2 (95th percentile), overcorrected to an MSS of -2.7, and a slightly metopic two-year MSS of 1.6 (10th percentile). Note that each patient is significantly overcorrected (MSS < 0) with a pronounced flattening of the frontal contour and widening of the temporal regions. At two-year follow-up in each case, the patient achieved a normalization of their head morphology as defined by MSS.

The relationships between preoperative severity and postoperative dysmorphology were examined with linear regression analysis. There was a significant linear relationship between preoperative severity and longitudinal morphology ($p < 0.001$, $R^2 = 0.70$). Per the regression equation, the postoperative MSS is expected to increase by approximately 0.3 for every unit increase in preoperative severity. In other words, patients who are more severely metopic in shape preoperatively are expected to have a slightly more metopic shape at two-year follow-up. There was no significant relationship between preoperative severity and immediate postoperative dysmorphology ($p = 0.42$, $R^2 = 0.01$). All patients are overcorrected to the maximum amount, and the degree of overcorrection is not dependent on preoperative severity.¹⁴ These relationships are displayed graphically in Figure 4. In addition, there was a significant positive linear relationship between immediate postoperative MSS and two-year postoperative MSS ($p = 0.004$, $R^2 = 0.45$). Patients who are overcorrected more significantly achieve a more normal head shape at two-year follow-up than those who are not overcorrected as much. This relationship is displayed graphically in Figure 5. There was no significant relationship between the length of time from surgery to two-year follow-up CT scan and longitudinal dysmorphology.

Discussion

This study investigated the preoperative skull shape severity and postoperative cranial morphology of 55 patients with metopic craniosynostosis who underwent FOA at a single institution using a validated machine learning algorithm, CranioRate™. We quantified the postoperative overcorrection that is achieved at our institution using our published standardized technique, wherein all patients receive maximum overcorrection allowed by their skin envelope.¹⁴ Two unique but related severity scores were generated for each scan: MSS, which utilizes a supervised ML algorithm to measure the degree of metopic dysmorphology of a given skull, and CMD, which utilizes a comprehensive statistical analysis of normal head shapes to measure the normalcy of a given skull, independent of diagnosis. Our results further validate that patients become “anti-metopic” with a negative MSS (normal = 0) following surgical overcorrection and gradually return to a normal skull shape over time. These data reinforce the value of CranioRate™ as an objective severity metric, and this study provides the first evidence that these metrics can be utilized to evaluate immediate postoperative changes in craniosynostosis.

Evaluation of postoperative results in patients with metopic craniosynostosis is typically subjective and historically involves categorical rating of head shape using some variation of the Whitaker Classification.^{1,11,20} There have been few significant advancements in postoperative evaluation of craniosynostosis in the past thirty-five years since the Whitaker Classification was first introduced¹² and there is a significant need for innovative postoperative evaluation tools in craniosynostosis research.²¹ We have shown that the novel algorithms presented in this study quantitatively stratify preoperative severity and postoperative morphology. The dual-algorithm approach leverages both CMD and MSS to follow patients postoperatively, both providing complementary information about skull shape.

Metopic craniosynostosis is treated with one of several primary surgical techniques – FOA, as described in this study, and suturectomy with spring implantation or postoperative orthotic therapy. Debate exists regarding the ideal operative technique,^{5,7,22} timing of surgery,^{23,24} and the severity of patients who require surgery.^{2,8} Patients in this study underwent FOA using our previously published standardized technique of fronto-orbital overcorrection.¹⁴ Overcorrection is an accepted method of compensating for subnormal postoperative skull growth in patients with metopic craniosynostosis.^{5,25} Many craniofacial surgeons and institutions have implemented overcorrection as a key to long-term normal aesthetic outcomes, and overcorrection has become a very powerful tool.

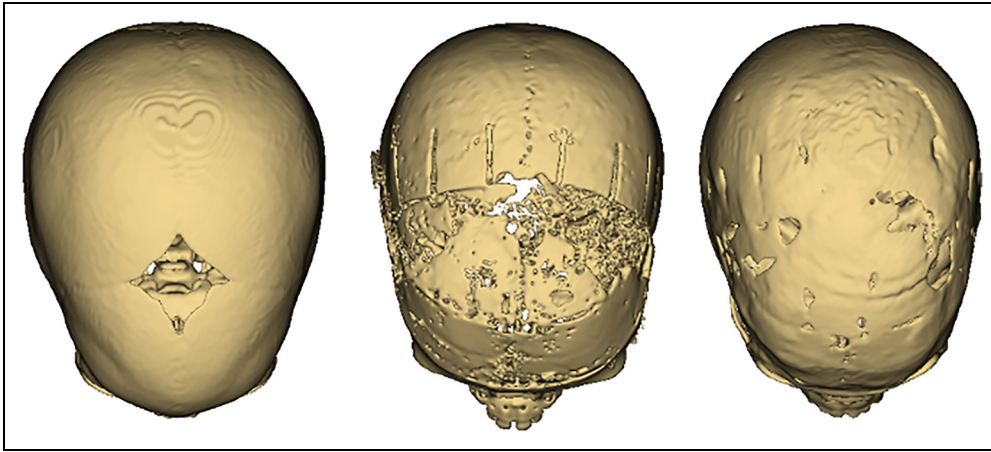


Figure 2. Example patient with a relatively mild preoperative MSS of 3.0 (20th percentile, left) overcorrected to an MSS of -3.5 (middle) and an acceptable two-year follow-up MSS of 0.5 (3rd percentile, right).

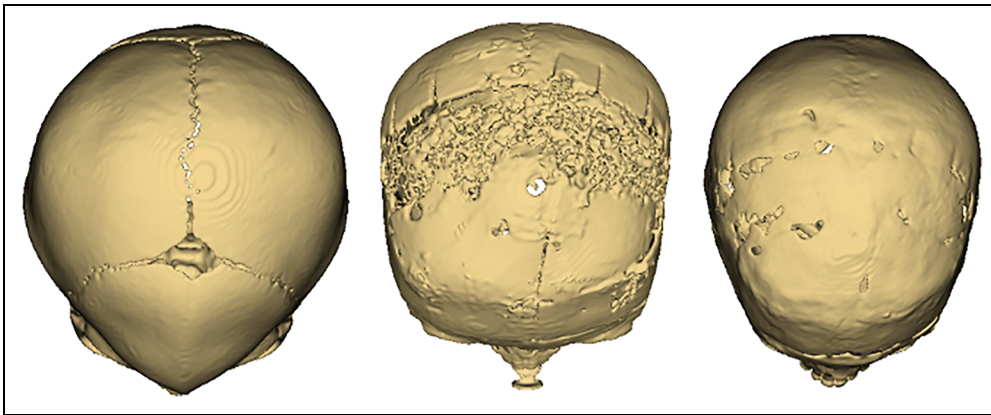


Figure 3. Example patient with a relatively severe preoperative MSS of 9.2 (95th percentile, left) overcorrected to an MSS of -2.7 (middle) and a slightly metopic longitudinal MSS of 1.6 (10th percentile, right).

However, the ideal degree of overcorrection is very difficult to quantify, and there has never been a definitive study that establishes a relationship between overcorrection and longitudinal head shape outcomes.

Recent results have demonstrated the efficacy of minimally invasive techniques in the operative management of metopic craniosynostosis.²⁶ In this historic cohort, no patients received minimally invasive surgery to treat metopic craniosynostosis. We currently offer minimally invasive techniques to select patients and are in the process of analyzing their head shape changes over time. The standardized operative technique that we used in this study allowed for a consistent shape morphology to be studied longitudinally and we are currently working to compare these results with those from patients who received minimally invasive surgery.

Surgical overcorrection in our cohort was confirmed by an immediate postoperative MSS of -2.0 ± 1.9 and CMD of 208.0 ± 27.1 . This combination of scores is what one would expect after overcorrection where features correlated with “metopiness” now deviate from normal in the opposite

manner. Indeed, a negative MSS can be considered a measure of “anti-metopic” skull morphology, and a higher CMD indicates that morphology is more abnormal, or overcorrected. This pattern of scores remains consistent at two-year follow-up, with an average MSS of 1.3 ± 1.1 and average CMD of 179.8 ± 28.1 . Previous literature has demonstrated a similar pattern of return towards metopic shape as a patient ages, as well.^{7,27} Thus, we present an objective postoperative trajectory of patients who have been overcorrected (Figure 1) and show that the degree of overcorrection correlates with longitudinal outcomes (Figure 5).

Furthermore, these are the first data to comprehensively quantify surgical overcorrection using postoperative imaging, and we propose that this will lead to a significant advancement in craniosynostosis treatment and research, where outcomes can be compared objectively among techniques and institutions. CranioRate™ provides the platform to answer previously proposed clinical questions such as the ideal operative technique, timing of intervention, and severity of craniosynostosis that necessitates surgery.

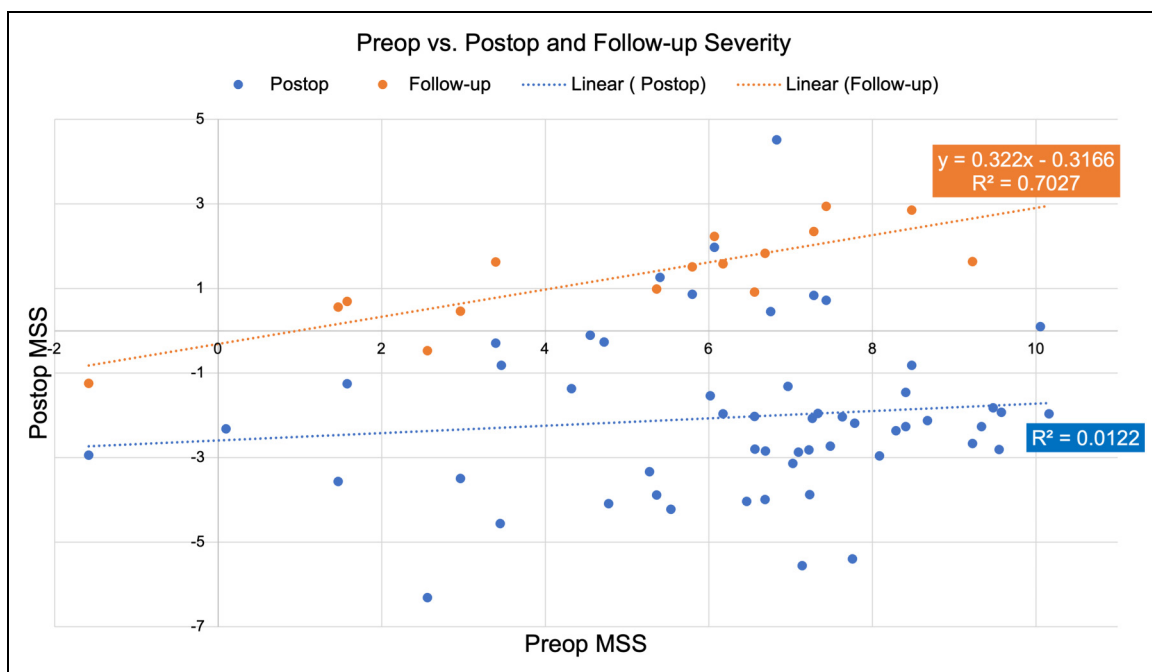


Figure 4. Relationships between preoperative MSS and (1) immediate postoperative MSS (blue) and (2) two-year postoperative MSS (orange). The resulting linear lines of best fit are displayed along with their corresponding R^2 values.

Prior research has shown a correlation between length of follow-up postoperatively and worsening aesthetic results.^{7,27} It is hypothesized that this long-term regression of shape may be due to tight soft tissue closure over the newly formed bandeau and temporal regions, although contributing factors such as bone flap devascularization must be further investigated. In addition, these results reinforce the need for surgical overcorrection in patients with metopic craniosynostosis. Our results demonstrate a significant relationship between preoperative severity and longitudinal severity, but no relationship between preoperative severity and immediate postoperative severity (Figure 4). The latter finding confirms the approach we employ at our institution, in which all patients are maximally overcorrected regardless of preoperative severity. In addition, we found a significant relationship between immediate postoperative severity and longitudinal severity (Figure 5), which suggests that patients who achieve a more significant overcorrection are “less metopic” at two-year follow-up. Together, these findings suggest that preoperative severity and degree of surgical overcorrection both contribute independently to longitudinal aesthetic results.

Other algorithmic approaches have been developed to evaluate craniosynostosis,^{4,9,10,28} but they do not provide comprehensive severity metrics and are not available at the point of care. CranioRateTM has been uniquely and specifically developed to assist craniofacial surgeons both clinically and in research endeavors. We have implemented a free, interactive point-of-care interface that is publicly available (craniorate.org) and provides detailed quantitative severity metrics (MSS scores and percentiles among a large series of 250+ patients with metopic craniosynostosis) for any patient whose CT image is

uploaded. We are currently working to expand CranioRateTM to other forms of craniosynostosis and demonstrated that its algorithm can evaluate 3D photographs as well.¹⁹

These results rely on the use of three separate CT images (preoperative, postoperative, two-year follow-up) in the evaluation and management of patients with craniosynostosis. The significant risk associated with childhood radiation exposure from radiation-inducing imaging is of particular concern in these patients.²⁹⁻³¹ As a result, we no longer routinely image these patients longitudinally and are developing a process to evaluate 3D photographs using CranioRateTM.¹⁹

There are several limitations of this study. First, not all patients in our cohort underwent two-year follow-up imaging, and our longitudinal analysis was limited to just 16 patients. In the future, we plan to include 3D photographs which we obtain for all patients at regular follow-up intervals. Indeed, we are currently building functionality in our toolset to process 3D photographs to use for longitudinal assessments and have recently published on this.¹⁹

In addition, we only present the results of patients who were treated at a single institution, though in the future, we plan to extend these analyses to evaluate the outcomes of other craniofacial surgeons and institutions. It will be valuable to compare the postoperative head shape changes of patients who have been operated on using different techniques and with varying degrees of overcorrection, as well as to increase the size of our cohort. While CranioRateTM addresses the need to quantify head shape in craniosynostosis, a normal MSS postoperatively does not necessarily indicate a good longitudinal result. The purpose of this metric is to grossly evaluate metopic craniosynostosis to study the trajectory of head growth postoperatively.

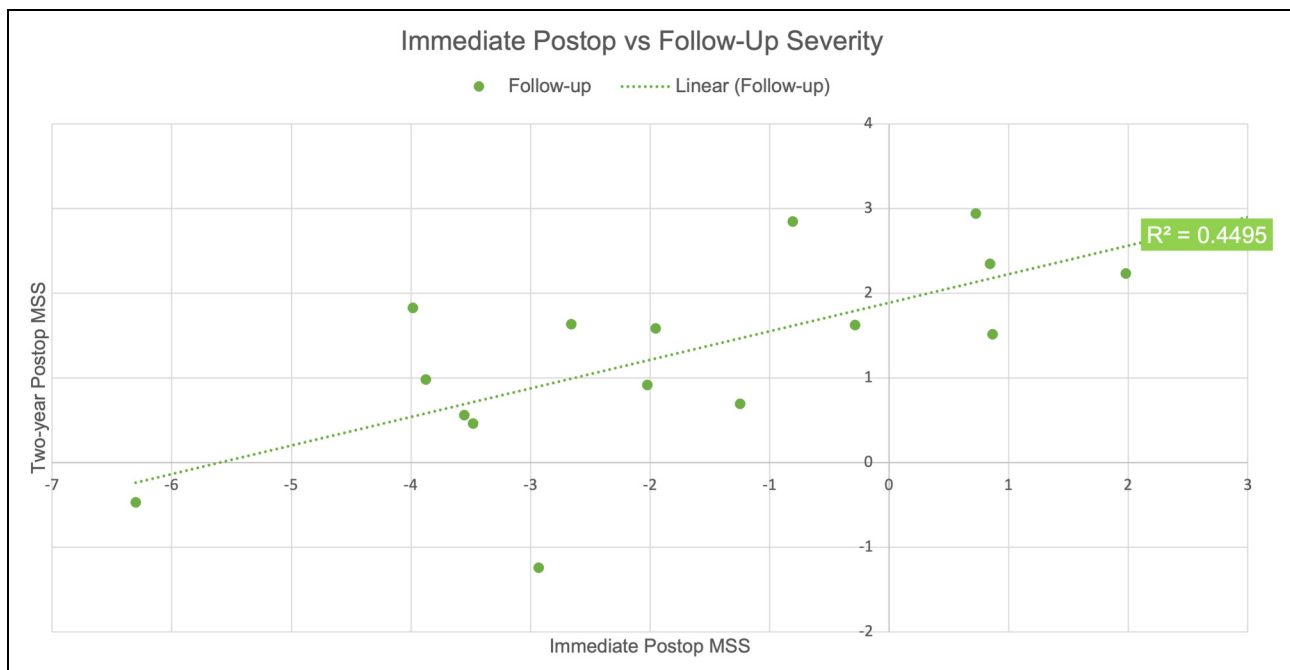


Figure 5. Relationship between immediate postoperative MSS and two-year postoperative MSS. The resulting linear line of best fit is displayed along with the resulting R^2 value from linear regression analysis. This figure demonstrates a positive correlation between immediate postoperative overcorrection (negative MSS) and less “metopic-ness” in longitudinal follow-up.

CranioRate™ should be used in conjunction with other clinical and anthropometric evaluations to holistically manage each patient.³² Finally, only one follow-up image was evaluated for each patient. After including 3D photographs, we plan to assess head shape growth longitudinally at regular follow-up intervals.

Conclusion

We propose a novel objective evaluation of head shape severity to quantify postoperative changes in metopic craniosynostosis after FOA. We have quantified the degree of surgical overcorrection that is achieved at our institution and track a large cohort of patients through two-year follow-up. Patients who were overcorrected approach a normal head shape after an average period of approximately two years. All patients had statistically similar postoperative metopic severity, with no significant association with preoperative severity, further confirming that every patient receives the same overcorrection procedure regardless of their presenting severity. However, more severe patients had worse longitudinal severity, which reinforces that regression to the metopic shape is a postoperative risk that increases with preoperative severity. This novel study demonstrates the utility of quantifying longitudinal morphologic changes in metopic patients.


Declaration of Conflicting Interests


The authors declared no potential conflicts of interest with respect to the research, authorship, and/or publication of this article.


Funding

The authors disclosed receipt of the following financial support for the research, authorship, and/or publication of this article: This research was supported in part by the National Institutes of Health, Plastic Surgery Foundation (NIBIB) through an R21 pilot grant (NIBIB-R21EB026061).

ORCID iDs

Zhazira Irgebay  <https://orcid.org/0000-0003-1373-3484>

Nicolás M. Kass  <https://orcid.org/0009-0009-2968-1253>

Jesse A. Goldstein  <https://orcid.org/0000-0002-5242-3844>

References

1. Wójcicki P, Prudel B. Trigenocephaly: Long-term results after surgical correction of metopic suture synostosis. *Adv Clin Exp Med.* May 2019;28(5):625-635. doi:10.17219/acem/90763
2. Jaskolka MS. Current controversies in metopic suture craniosynostosis. *Oral Maxillofac Surg Clin North Am.* Nov 2017;29(4):447-463. doi:10.1016/j.coms.2017.07.003
3. Burge J, Saber NR, Looi T, et al. Application of CAD/CAM pre-fabricated age-matched templates in cranio-orbital remodeling in craniosynostosis. *J Craniofac Surg.* Sep 2011;22(5):1810-1813. doi:10.1097/SCS.0b013e31822e8045
4. Porras AR, Tu L, Tsering D, et al. Quantification of head shape from three-dimensional photography for presurgical and postsurgical evaluation of craniosynostosis. *Plast Reconstr Surg.* Dec 2019;144(6):1051e-1060e. doi:10.1097/prs.0000000000006260
5. Fearon JA, Dithakasem K, Chan WJ, Herbert M. Long-Term growth following trigonocephaly repairs: Are overcorrections

- necessary? *Plast Reconstr Surg.* Mar 2020;145(3):583e-590e. doi:10.1097/prs.00000000000006576
6. Selber JC, Brooks C, Kurichi JE, Temmen T, Sonnad SS, Whitaker LA. Long-term results following fronto-orbital reconstruction in nonsyndromic unicoronal synostosis. *Plast Reconstr Surg.* May 2008;121(5):251e-260e. doi:10.1097/PRS.0b013e31816a9f88
 7. Lwin CT, Richardson D, Duncan C, May P. Relapse in fronto-orbital advancement: A pilot study. *J Craniofac Surg.* Jan 2011;22(1):214-216. doi:10.1097/SCS.0b013e3181f76081
 8. Beckett JS, Chadha P, Persing JA, Steinbacher DM. Classification of trigonocephaly in metopic synostosis. *Plast Reconstr Surg.* Sep 2012;130(3):442e-447e. doi:10.1097/PRS.0b013e31825dc244
 9. Marcus JR, Domeshek LF, Loyd AM, et al. Use of a three-dimensional, normative database of pediatric craniofacial morphology for modern anthropometric analysis. *Plast Reconstr Surg.* Dec 2009;124(6):2076-2084. doi:10.1097/PRS.0b013e3181bf7e1b
 10. Anolik RA, Allori AC, Pourtaheri N, Rogers GF, Marcus JR. Objective assessment of the interfrontal angle for severity grading and operative decision-making in metopic synostosis. *Plast Reconstr Surg.* May 2016;137(5):1548-1555. doi:10.1097/prs.0000000000002052
 11. Whitaker LA, Bartlett SP, Schut L, Bruce D. Craniosynostosis: An analysis of the timing, treatment, and complications in 164 consecutive patients. *Plast Reconstr Surg.* Aug 1987;80(2):195-212. doi:10.1097/00006534-198708000-00006
 12. Wes AM, Naran S, Sun J, et al. The Whitaker classification of craniosynostosis outcomes: An assessment of interrater reliability. *Plast Reconstr Surg.* Oct 2017;140(4):579e-586e. doi:10.1097/prs.0000000000003688
 13. Bhalodia R, Dvoracek LA, Ayyash AM, Kavan L, Whitaker R, Goldstein JA. Quantifying the severity of metopic craniosynostosis: A pilot study application of machine learning in craniofacial surgery. *J Craniofac Surg.* May/June 2020;31(3):697-701. doi:10.1097/scs.00000000000006215
 14. Pfaff MJ, Bruce MK, Erpenbeck S, et al. A three-dimensional-based morphometric analysis of a standardized overcorrection technique for fronto-orbital advancement in metopic craniosynostosis. *Cleft Palate Craniofac J.* 2023;60(3):268-273. doi:10.1177/10556656211062843
 15. Junn A, Dinis J, Hauc SC, et al. Validation of artificial intelligence severity assessment in metopic craniosynostosis. *Cleft Palate Craniofac J.* Mar 2023;60(3):274-279. doi:10.1177/10556656211061021
 16. Anstadt EE, Tao W, Guo E, et al. Quantifying the severity of metopic craniosynostosis using unsupervised machine learning. *Plast Reconstr Surg.* Feb 1 2023;151(2):396-403. doi:10.1097/PRS.00000000000009853
 17. Beiriger JW, Tao W, Bruce MK, et al. Craniorate: An image-based, deep-phenotyping analysis toolset and online clinician interface for metopic craniosynostosis. *Plast Reconstr Surg.* Jan 1 2024;153(1):112e-119e. doi:10.1097/PRS.00000000000010452
 18. Blum JD, Beiriger J, Villavisanis DF, et al. Machine learning in metopic craniosynostosis: Does phenotypic severity predict long-term esthetic outcome? *J Craniofac Surg.* Jan-Feb 01 2023;34(1):58-64. doi:10.1097/SCS.00000000000008868
 19. Bruce MK, Tao W, Beiriger J, et al. 3D photography to quantify the severity of metopic craniosynostosis. *Cleft Palate Craniofac J.* Aug 2023;60(8):971-979. doi:10.1177/10556656221087071
 20. Marchac D, Renier D, Broumand S. Timing of treatment for craniosynostosis and facio-craniosynostosis: A 20-year experience. *Br J Plast Surg.* Jun 1994;47(4):211-222. doi:10.1016/0007-1226(94)90001-9
 21. Schulz M, Liebe-Püschel L, Seelbach K, et al. Quantitative and qualitative comparison of morphometric outcomes after endoscopic and conventional correction of sagittal and metopic craniosynostosis versus control groups. *Neurosurg Focus.* Apr 2021;50(4):E2. doi:10.3171/2021.1.Focus20988
 22. Arab K, Fischer S, Bahtti-Softeland M, Maltese G, Kolby L, Tarnow P. Comparison between two different isolated craniosynostosis techniques: Does it affect cranial bone growth? *J Craniofac Surg.* Jul 2016;27(5):e454-e457. doi:10.1097/scs.00000000000002769
 23. Utria AF, Lopez J, Cho RS, et al. Timing of cranial vault remodeling in nonsyndromic craniosynostosis: A single-institution 30-year experience. *J Neurosurg Pediatr.* Nov 2016;18(5):629-634. doi:10.3171/2016.5.Peds1663
 24. Layliev J, Gill R, Spear M, Cifuentes J, Wang L, Kelly KJ. The optimal timing for primary cranial vault reconstruction in nonsyndromic craniosynostosis. *J Craniofac Surg.* Sep 2016;27(6):1445-1452. doi:10.1097/scs.00000000000002730
 25. Bennett KG, Liang F, Ranganathan K, Muraszko KM, Vercler CJ, Buchman SR. Surgical hypercorrection of trigonocephaly: Evaluation of surgical outcomes. *J Craniofac Surg.* Jan 2018;29(1):56-61. doi:10.1097/scs.00000000000004044
 26. Ha AY, Skolnick GB, Chi D, et al. School-aged anthropometric outcomes after endoscopic or open repair of metopic synostosis. *Pediatrics.* Sep 2020;146(3):e20200238. doi:10.1542/peds.2020-0238
 27. Wes AM, Paliga JT, Goldstein JA, Whitaker LA, Bartlett SP, Taylor JA. An evaluation of complications, revisions, and long-term aesthetic outcomes in nonsyndromic metopic craniosynostosis. *Plast Reconstr Surg.* Jun 2014;133(6):1453-1464. doi:10.1097/prs.0000000000000223
 28. Graf AR, Klement KA, Denny AD. Quantifying craniometric change early after fronto-orbital advancement in metopic synostosis. *J Craniofac Surg.* Oct 2016;27(7):1727-1731. doi:10.1097/scs.00000000000002977
 29. Fearon JA, Singh DJ, Beals SP, Yu JC. The diagnosis and treatment of single-sutural synostoses: Are computed tomographic scans necessary? *Plast Reconstr Surg.* Oct 2007;120(5):1327-1331. doi:10.1097/01.prs.0000279477.56044.55
 30. Engel M, Castrillon-Oberndorfer G, Hoffmann J, Freudlsperger C. Value of preoperative imaging in the diagnostics of isolated suture synostosis: A risk-benefit analysis. *J Plast Reconstr Aesthet Surg.* Sep 2012;65(9):1246-1251. doi:10.1016/j.bjps.2012.03.038
 31. Bruce MK, Mittal AM, Whitt DS, et al. Computed tomography associated radiation exposure in children with craniosynostosis. *Childs Nerv Syst.* Aug 2021;37(8):2635-2641. doi:10.1007/s00381-021-05254-0
 32. Baş NS, Baş S. Craniometric measurements and surgical outcomes in trigonocephaly patients who underwent surgical treatment. *Cureus.* Mar 3 2021;13(3):e13676. doi:10.7759/cureus.13676