

Clinical EP Studies Lab

Ravi Ranjan

Division of Cardiology

ravi.ranjan@hsc.utah.edu

Normal ECG

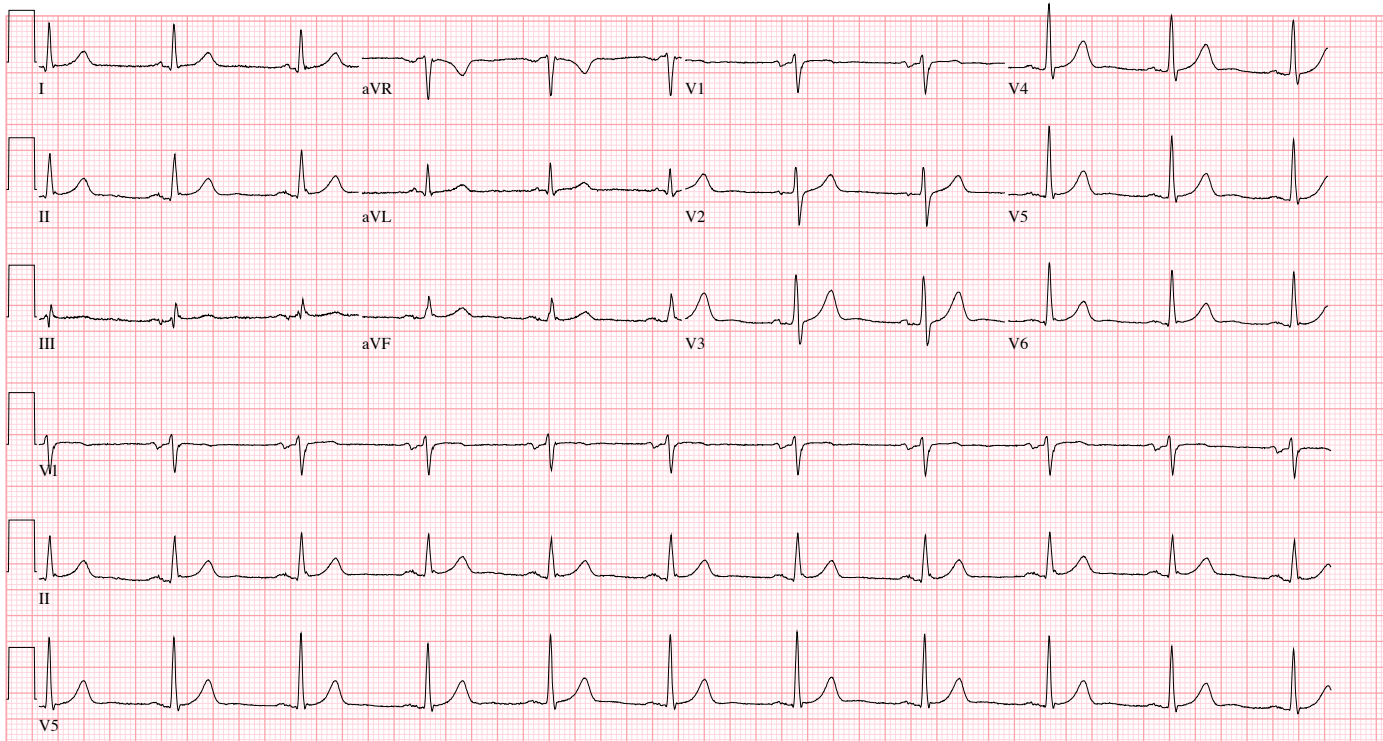
UNIVERSITY HEALTH CARE

Vent. rate	62	BPM
PR interval	154	ms
QRS duration	92	ms
QT/QTc	402/408	ms
P-R-T axes	36 38	40

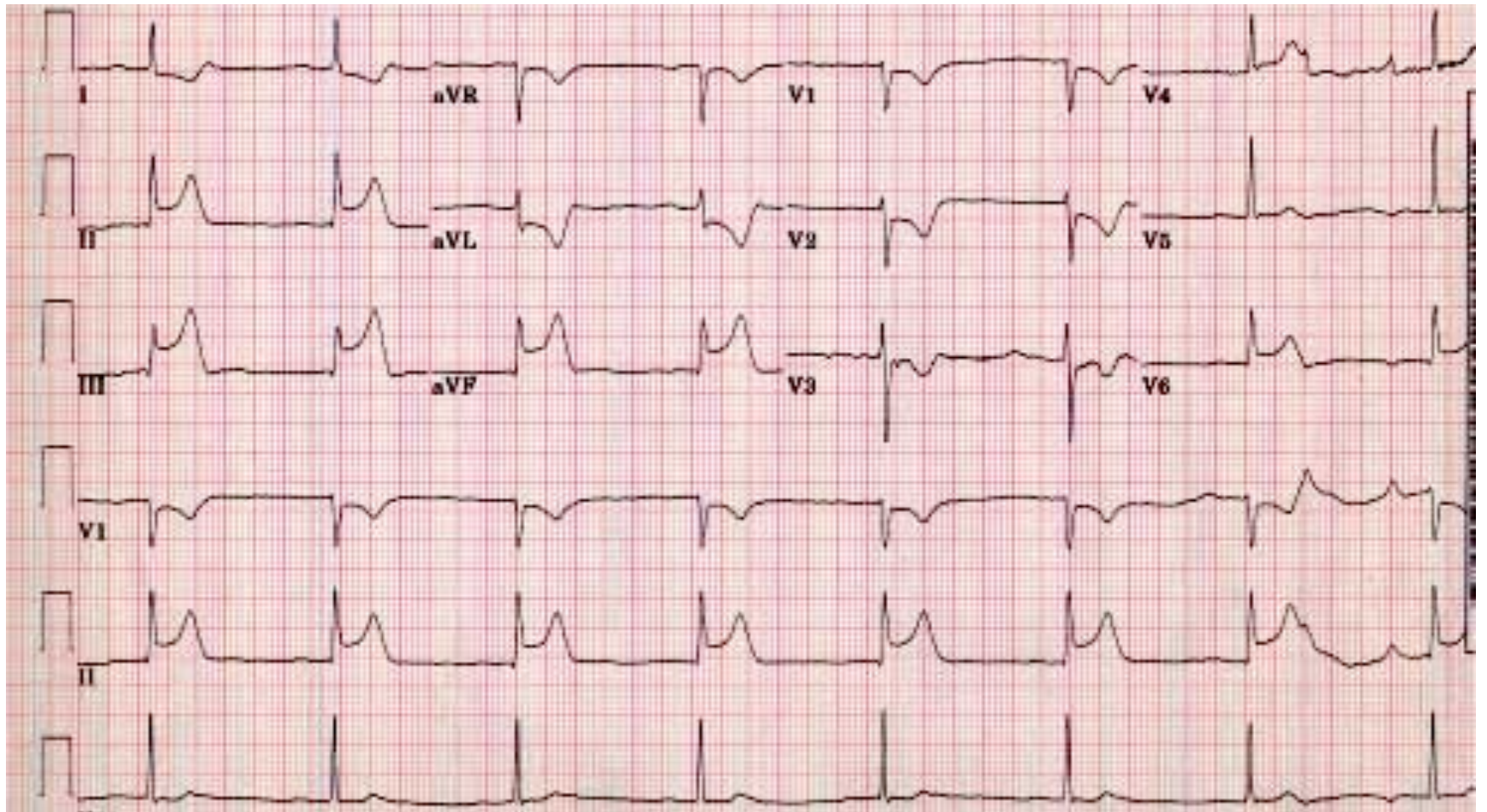
Technician: AMBER
Test ind:780.2

Referred by: MOHAMED HAMDAN

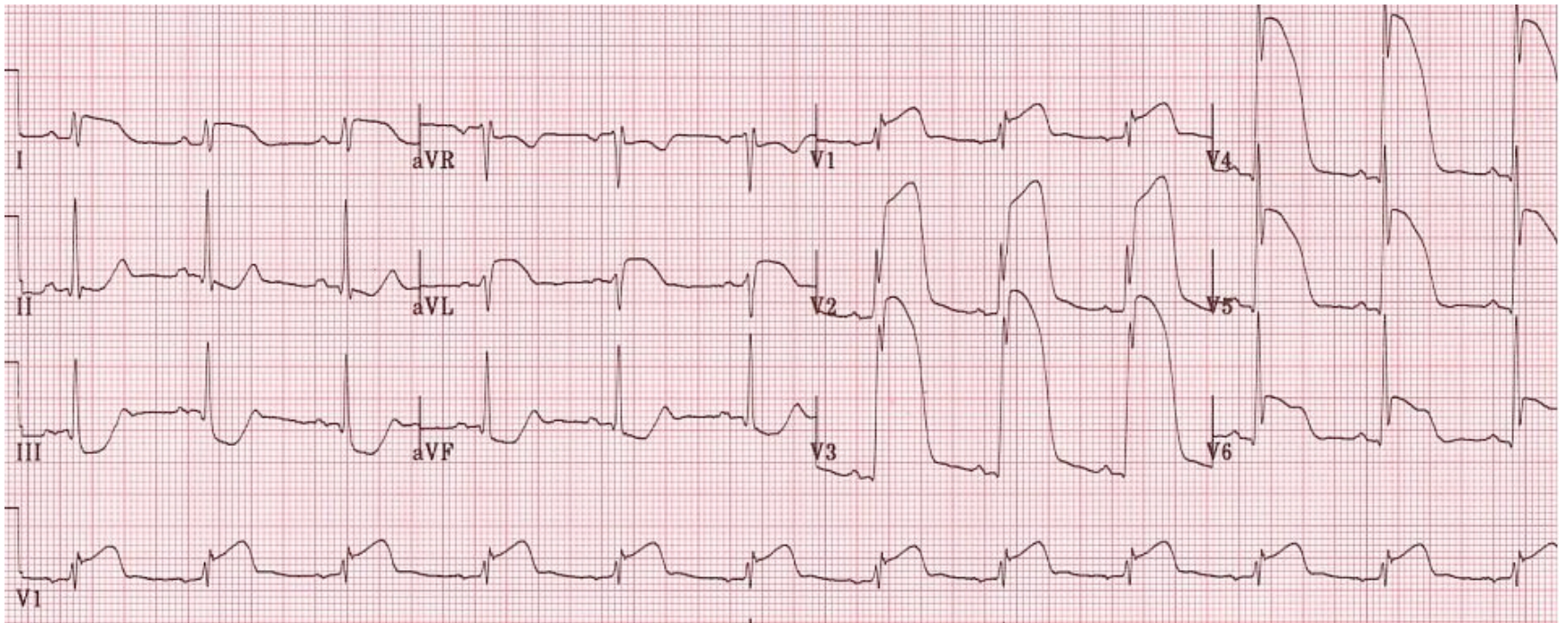
Confirmed By: Ravi Ranjan



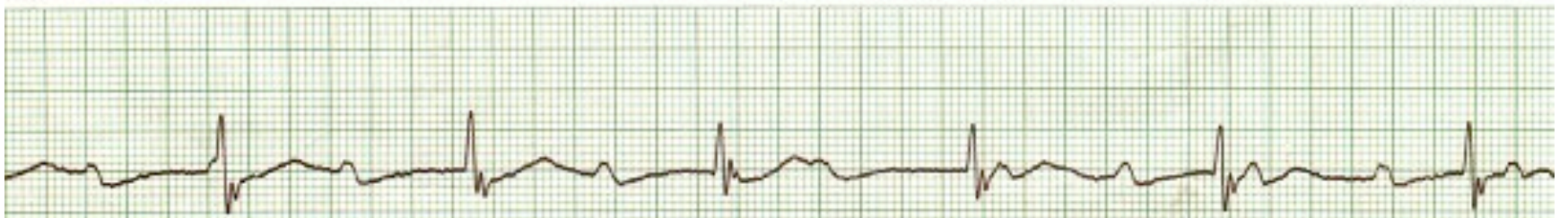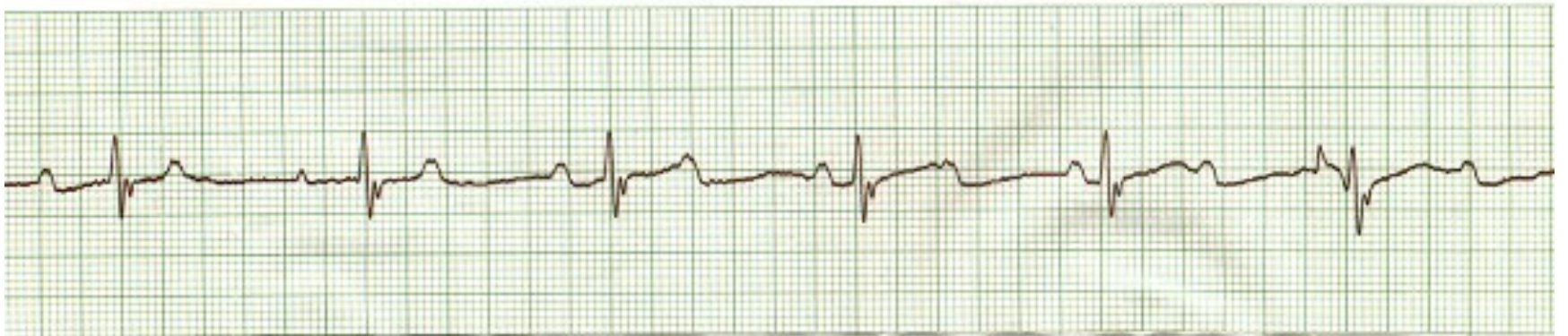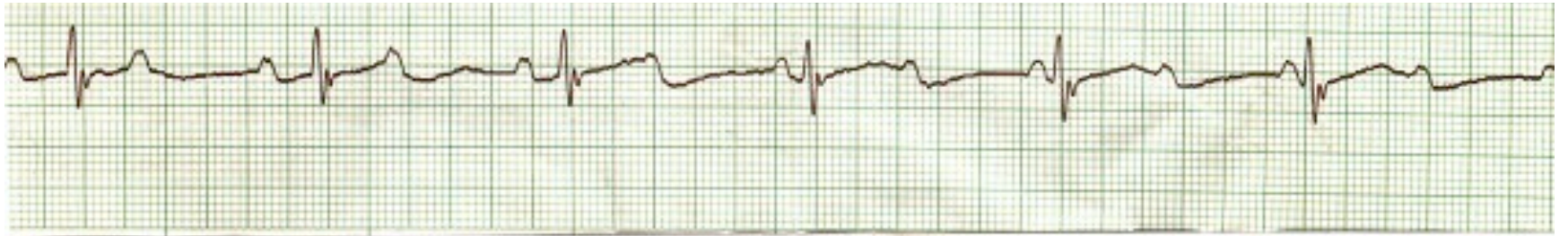STEMI



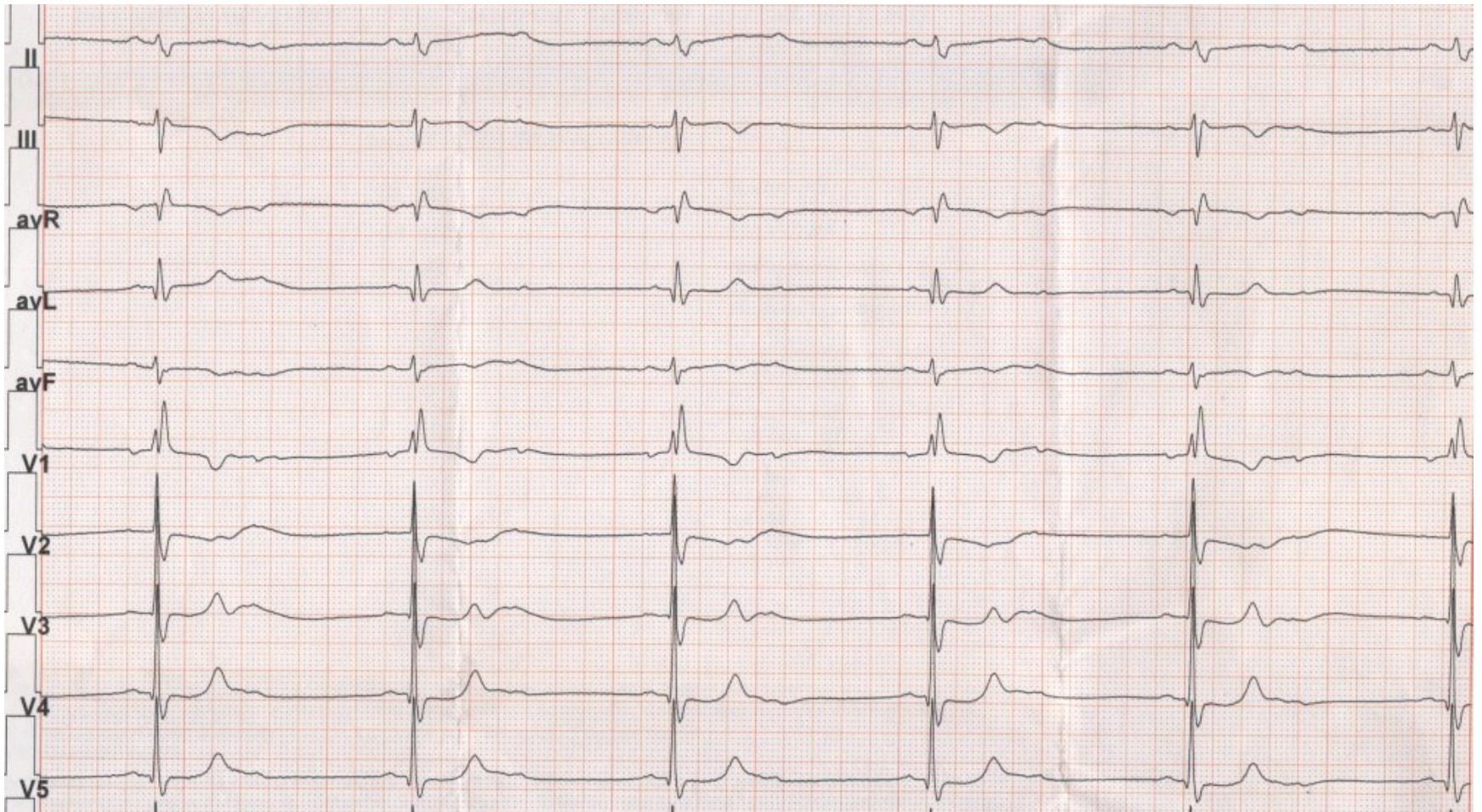
STEMI



Heart Block



2:1 Heart Block



LBBB

UNIVERSITY HEALTH CARE

Vent. rate	64	BPM
PR interval	234	ms
QRS duration	184	ms
QT/QTc	516/532	ms
P-R-T axes	-23 -57	117

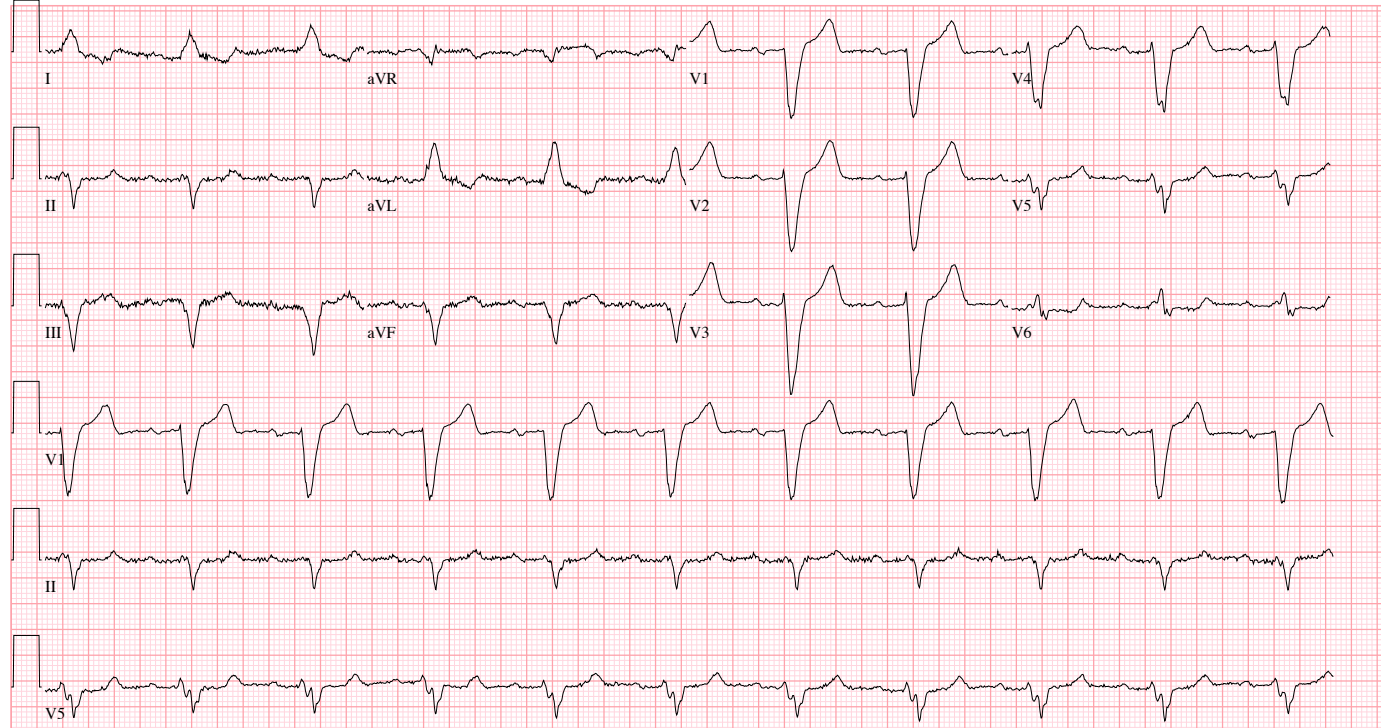
Technician: TSS
Test ind: VT

Referred by: HAMDAN

Confirmed By: Ravi Ranjan

Comment: 185310459

Study:



RBBB

UNIVERSITY HEALTH CARE

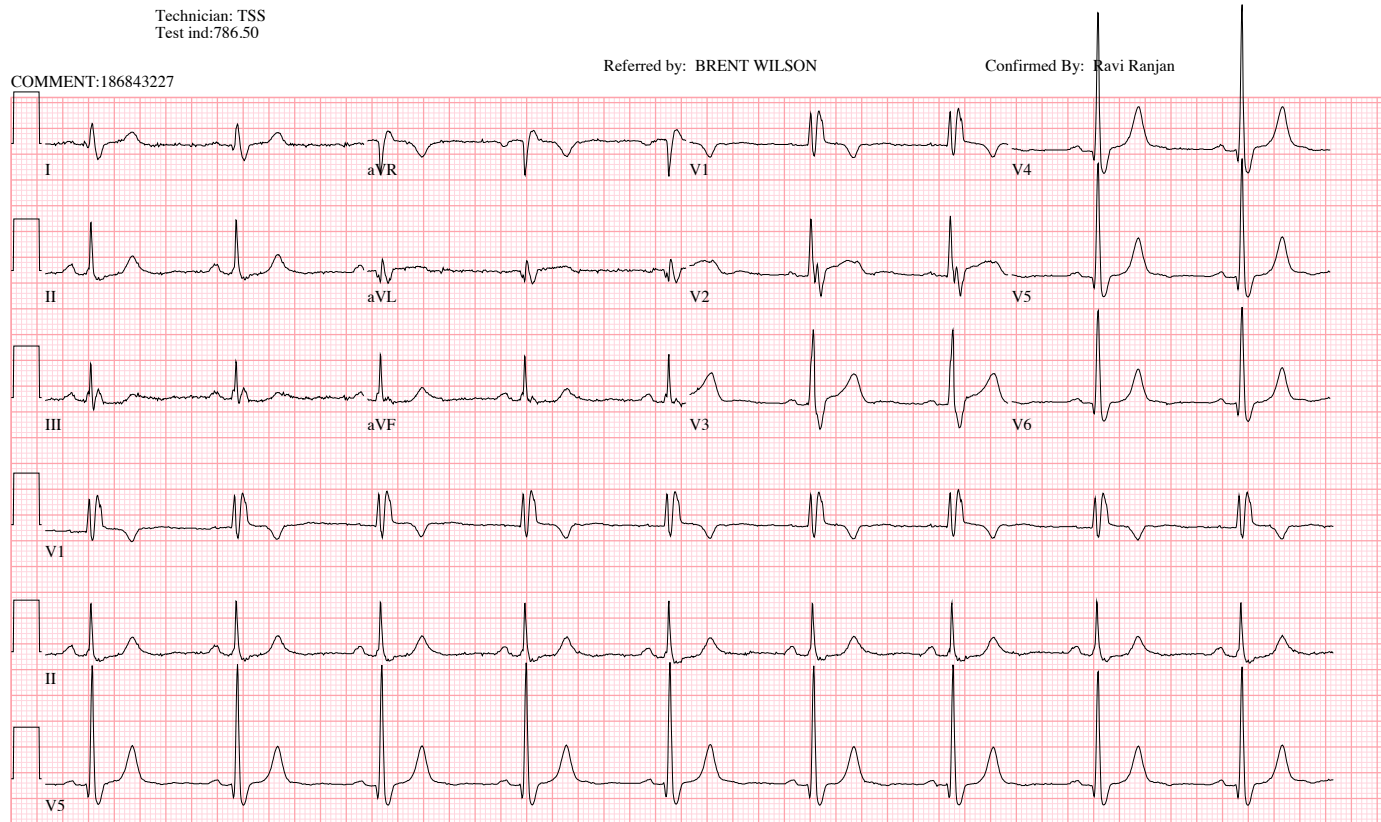
Vent. rate	53	BPM
PR interval	174	ms
QRS duration	138	ms
QT/QTc	458/429	ms
P-R-T axes	76 78	46

Technician: TSS
Test ind:786.50

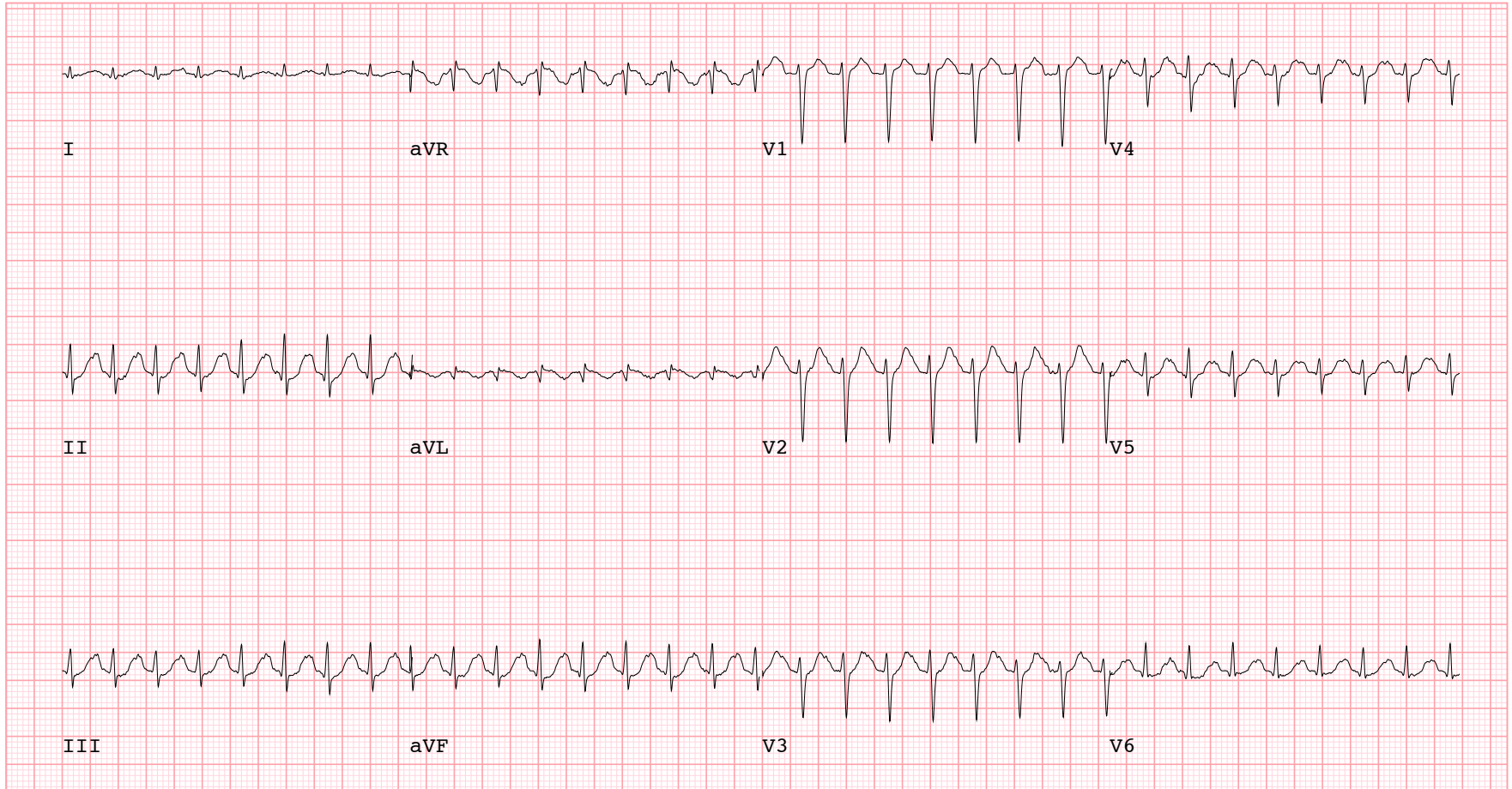
Referred by: BRENT WILSON

Confirmed By: Ravi Ranjan

COMMENT:186843227



Supra Ventricular Tachycardia



GE Medical Systems IT
CASE V5.02

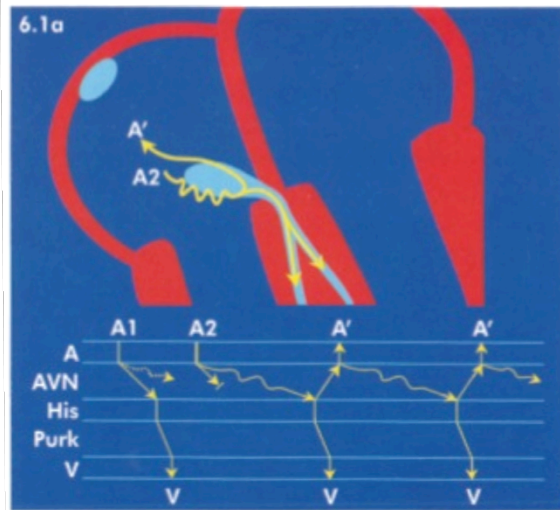
25mm/s 10mm/mV 60Hz 0.01-40Hz S+ HR(V1,V2)

Supra Ventricular Tachycardia (SVT)

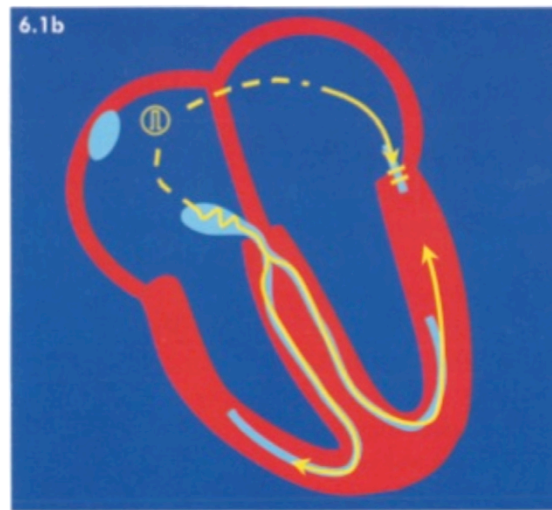
- AVNRT – AV nodal re-entrant tachycardia
- AVRT – Atrio-ventricular re-entrant tachycardia
- AT – atrial tachycardia

SVT initiation

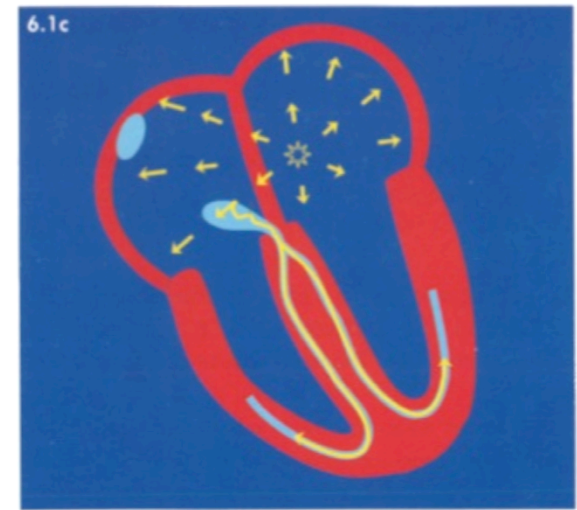
AVNRT
AV nodal re-entrant
tachycardia



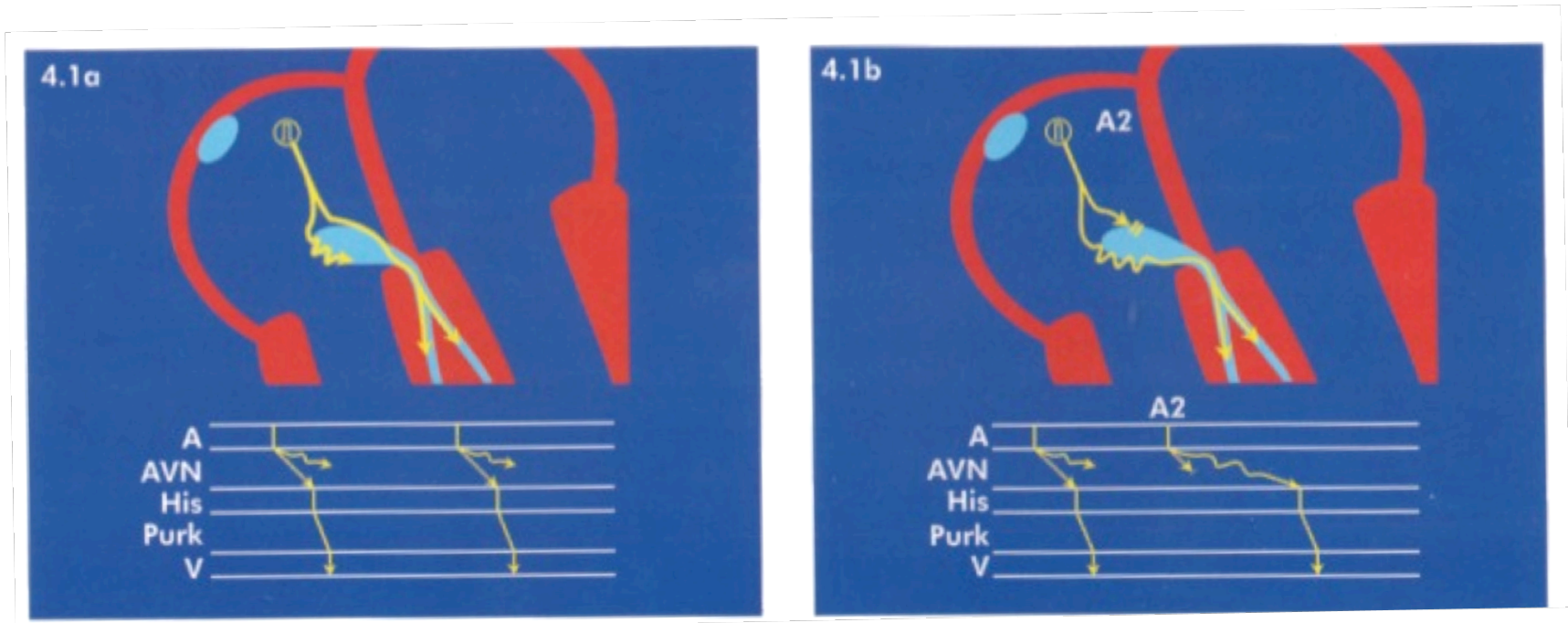
ORT
Orthodromic re-entrant
tachycardia



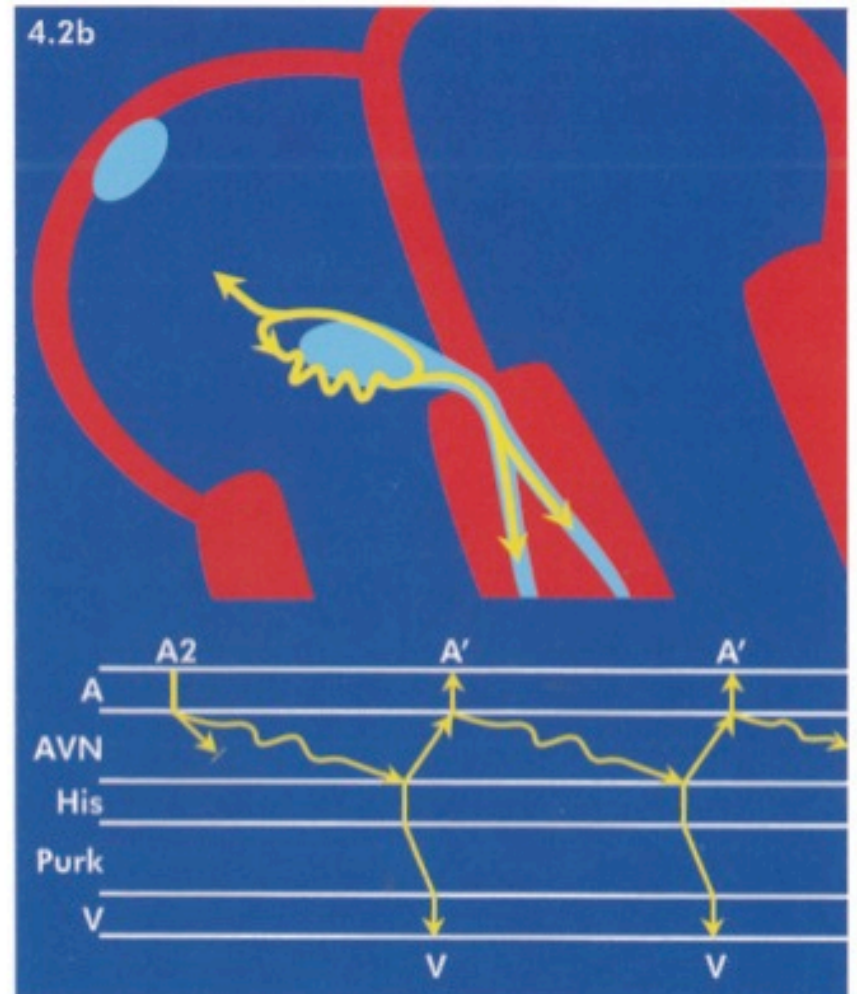
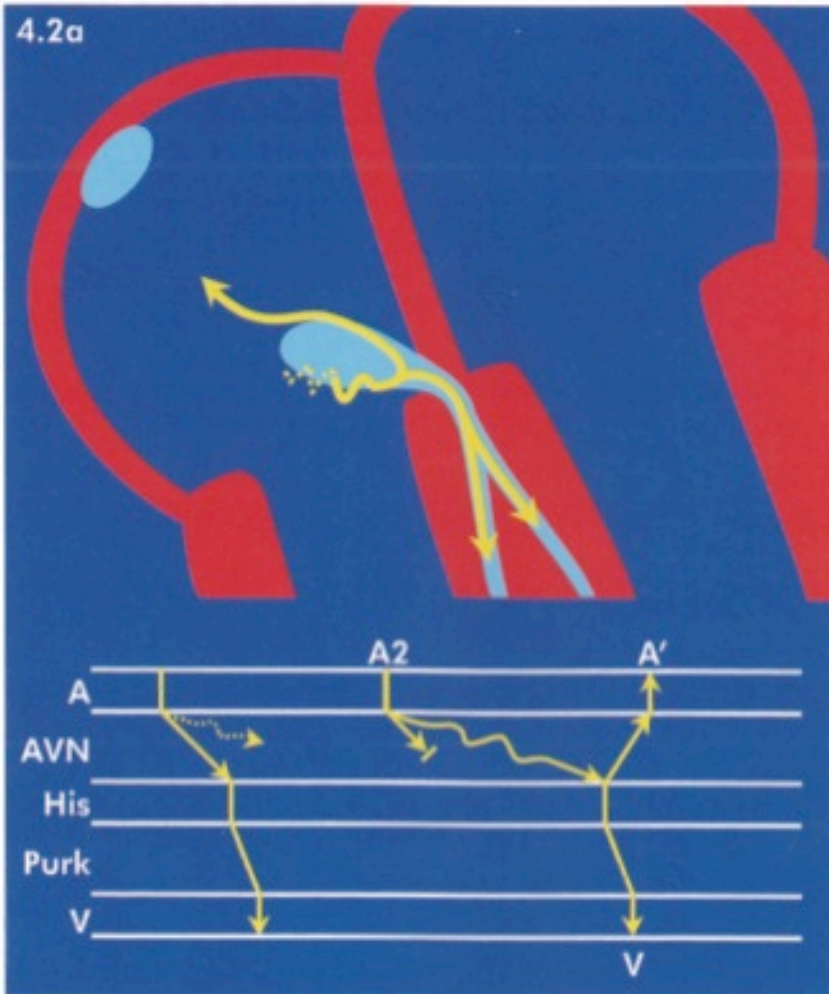
AT
Atrial Tachycardia



Dual Node Pathway



AVNRT



Basic EP recordings

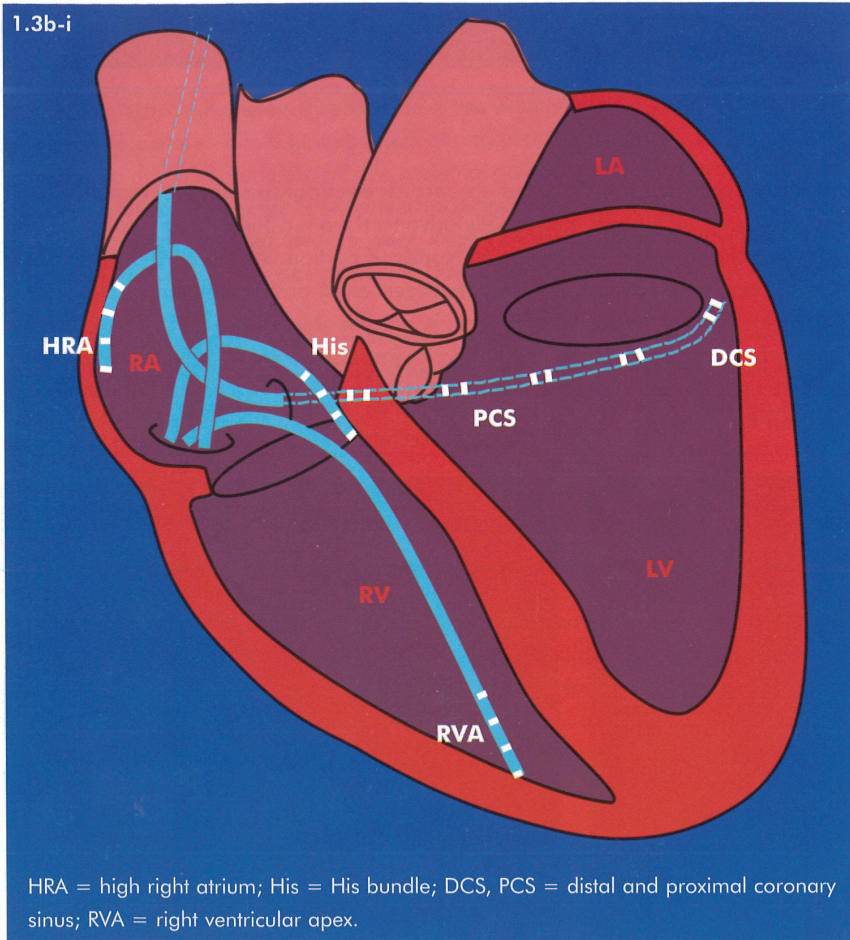
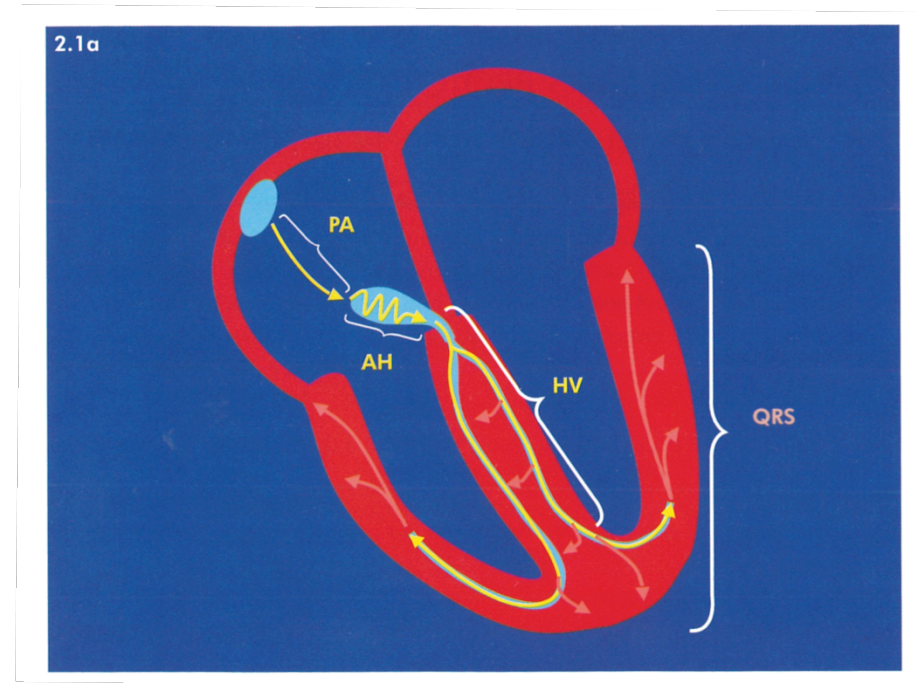
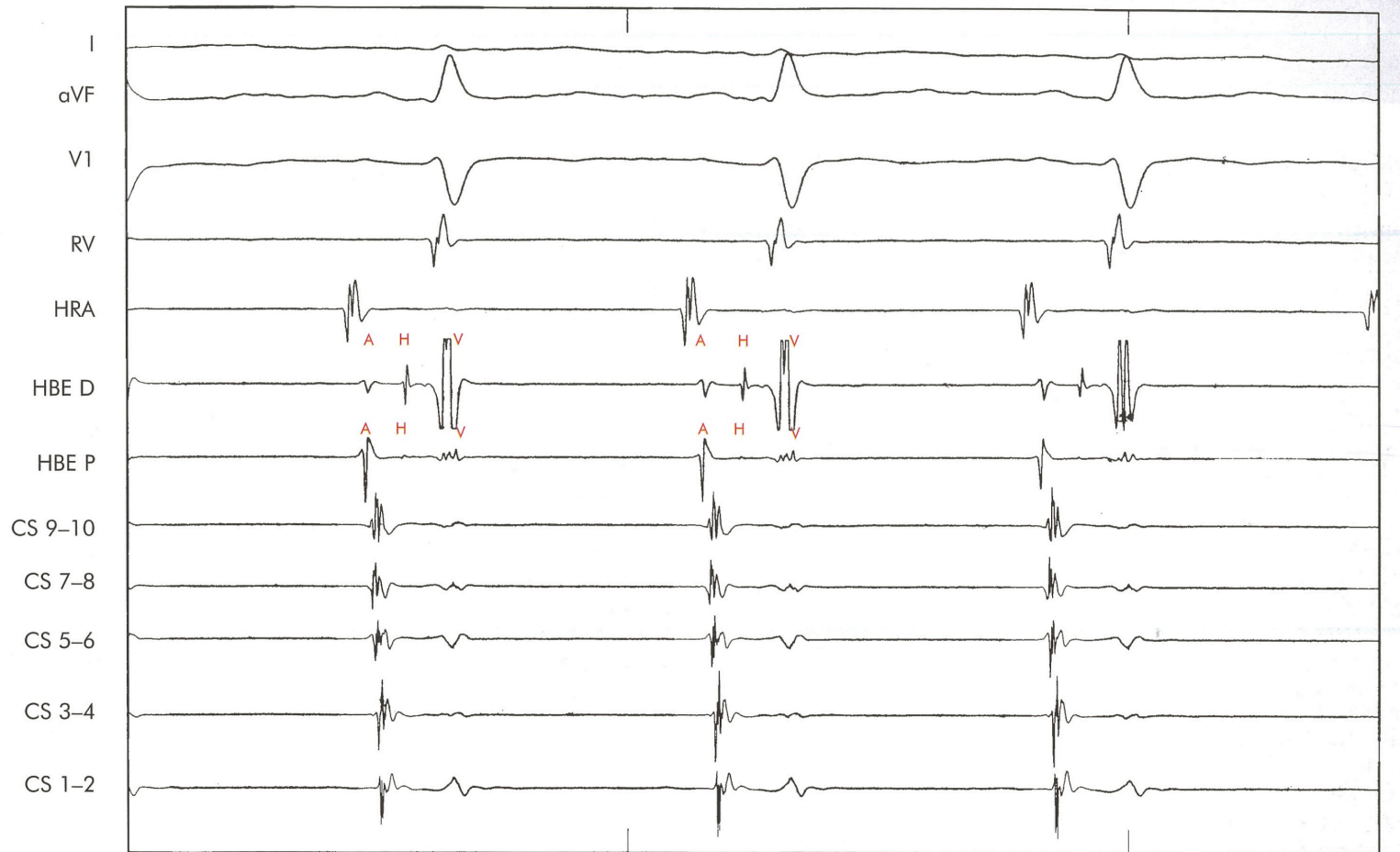

Figure 1.3b-i illustrates the standard catheter positions for a 'four-wire' diagnostic EP study.

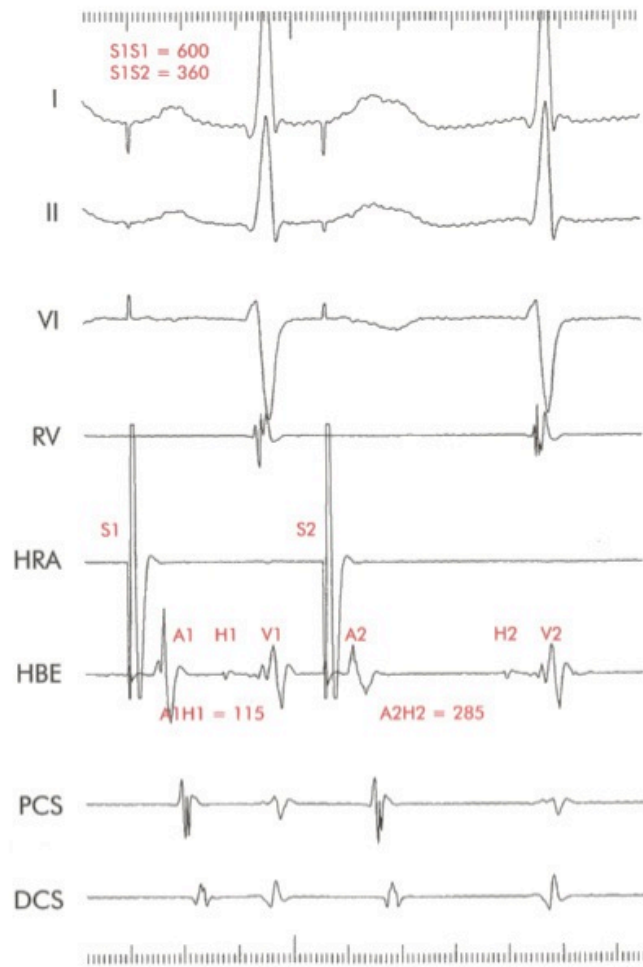


Basic EP recordings

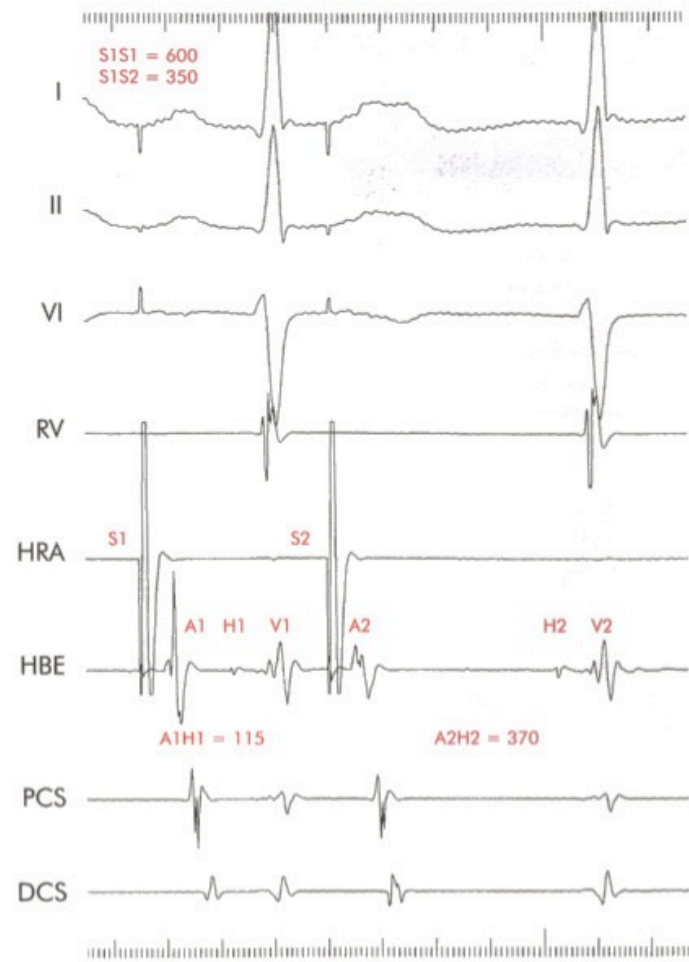


Tracing 1.3 Electrograms displayed during standard four-wire study in sinus rhythm. Although all twelve surface ECG leads are recorded, only three approximately orthogonal leads are shown, for clarity. The right ventricular apex (RV) and high right atrium (HRA) leads show sharp single chamber electrograms. The His bundle catheter records activity adjacent to the AV node; the distal bipole (HBE D) favoring the His bundle electrogram (H) and the adjacent ventricular myocardium (V), while the proximal bipole (HBE P) shows a large atrial electrogram (A). Note that, although the ventricular spike recorded by the His bundle comes from tissue adjacent to the bundle of His, the earliest ventricular activity is at the apex (RV). The electrograms recorded by the bipoles of the decapolar coronary sinus catheter are labeled CS 9–10 (proximal) to CS 1–2 (distal); each shows a sharp atrial electrogram followed by a smaller ventricular electrogram.

Dual Node Pathway

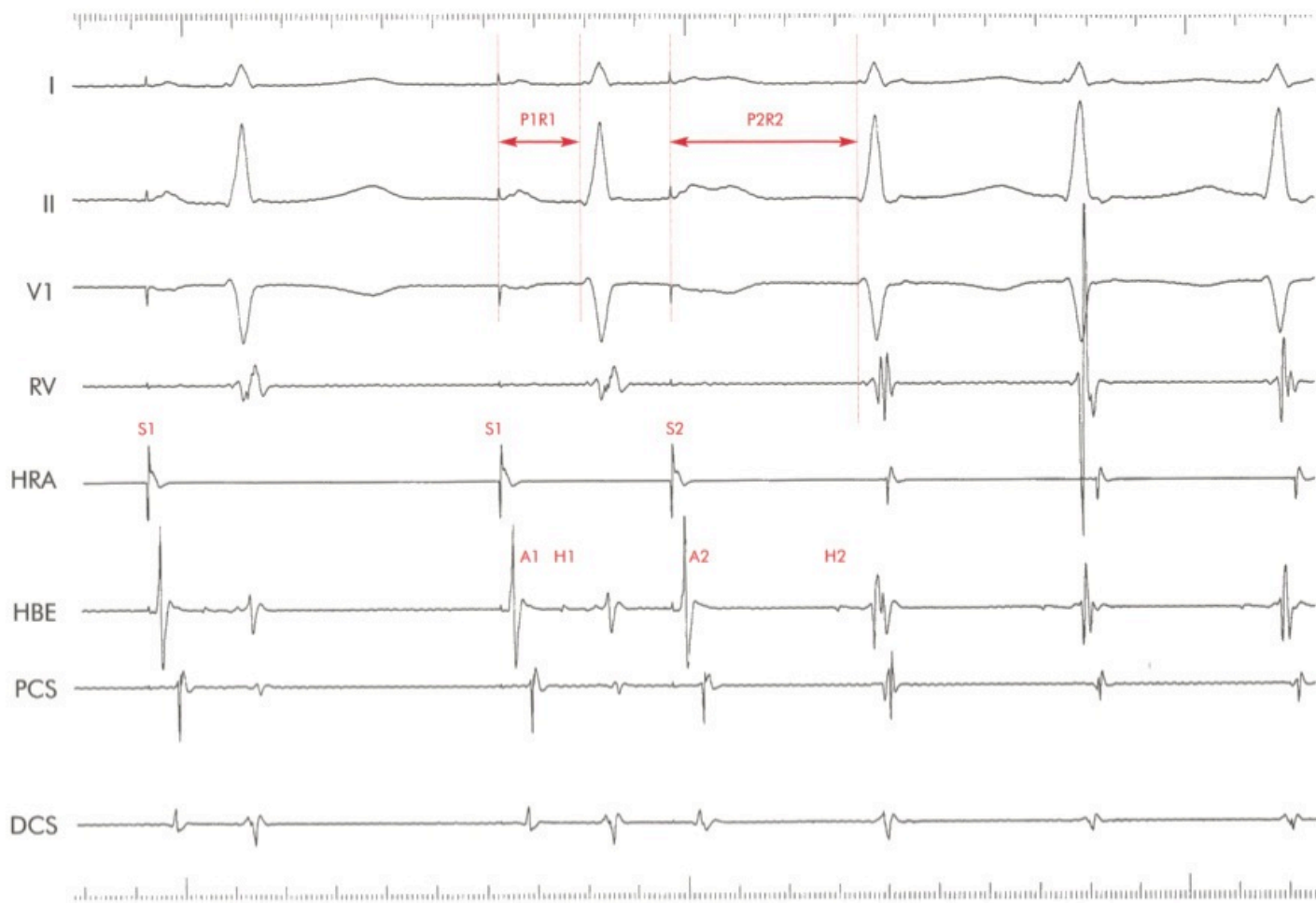


Tracing 4.1a Following an atrial drive train (S1S1 = 600 ms), an atrial extrastimulus is given (S1S2 = 360 ms). The AH interval of the extrastimulus (A2H2) is greater than that of the drive train (A1H1) because of decrement in the AV node.



Tracing 4.1b An atrial extrastimulus is delivered in the same patient, with a slightly shorter coupling interval (S1S1 = 600 ms, S1S2 = 350 ms). The A1A2 is less than the ERP of the fast pathway, which blocks, and the impulse can now only conduct down the slow pathway. The AH interval of the extrastimulus increases from 285 to 370 ms, a 'jump' of 85 ms.

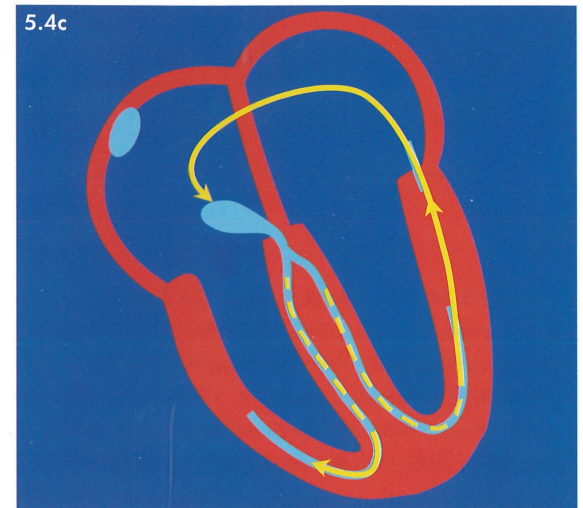
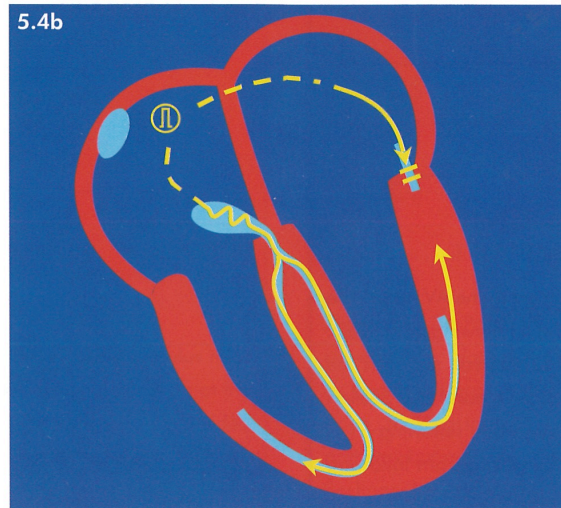
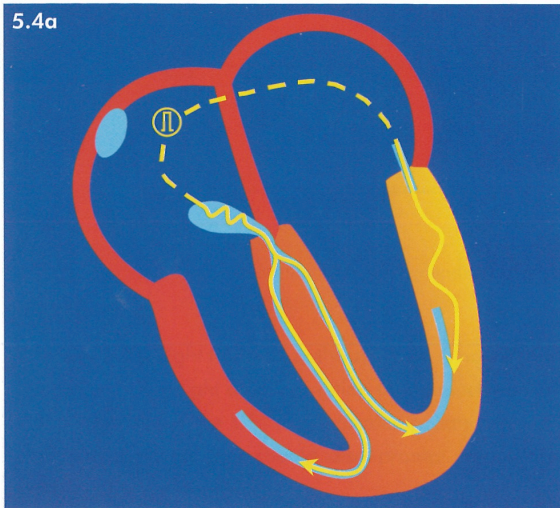
AVNRT



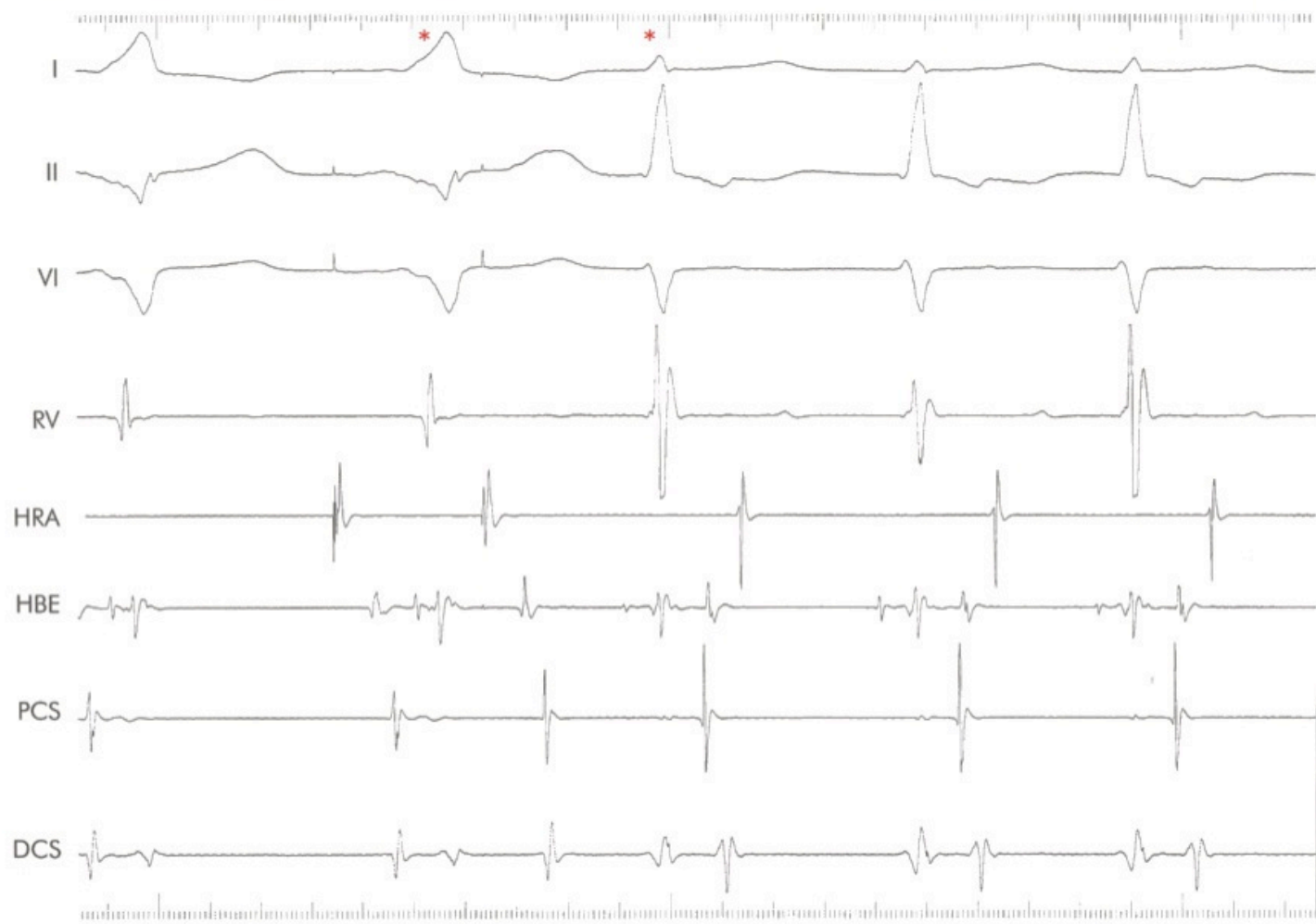Tracing 6.1a The onset of tachycardia may differ according to the tachycardia mechanism. AV nodal reentry is induced by an atrial extrastimulus, which results in block in the fast pathway and conduction over the slow pathway. The AH prolongation is obvious but the mechanism can also be seen in the surface leads.

AVRT – initiation

Orthodromic Re-entrant Tachycardia (ORT)

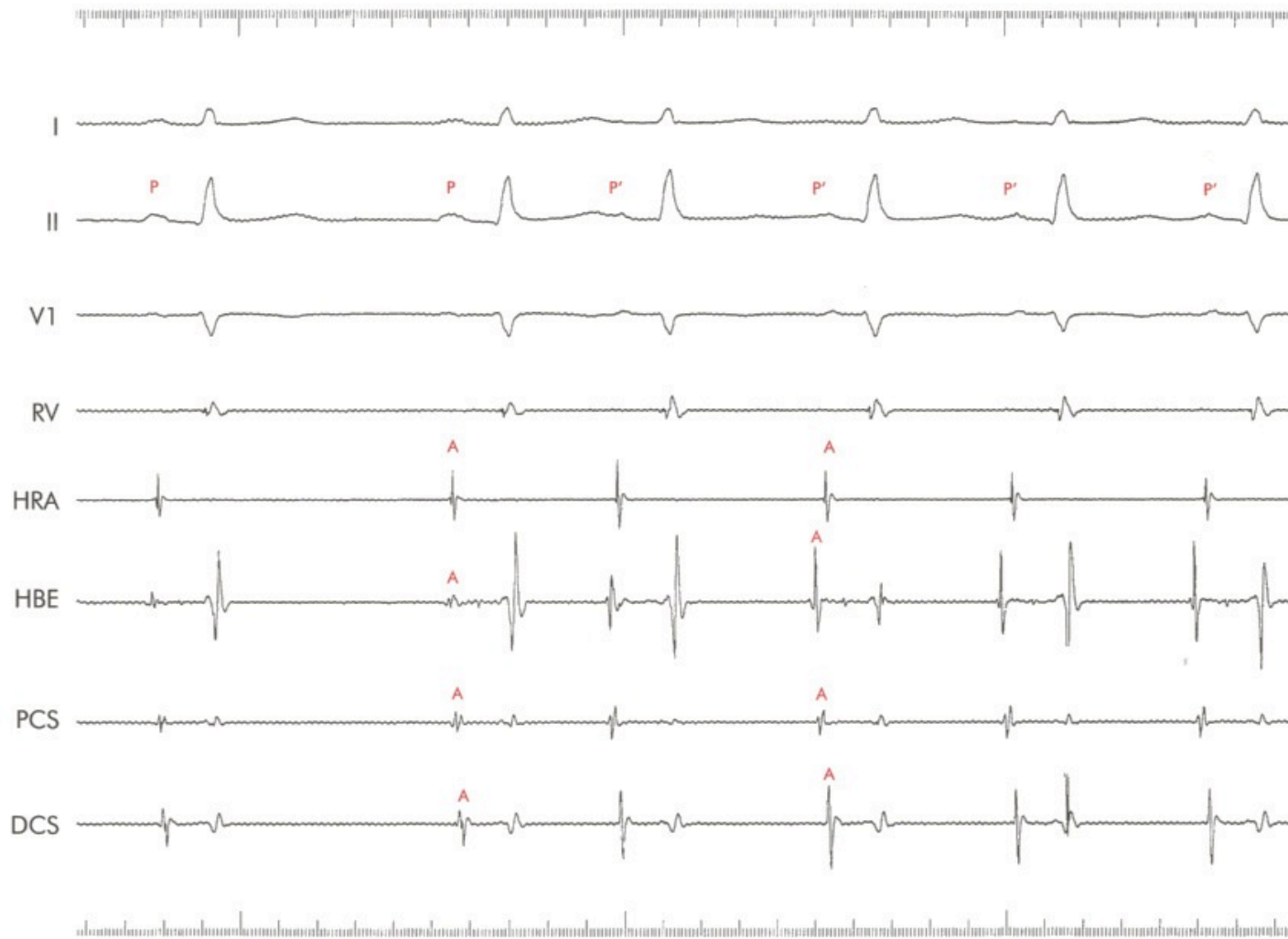


ORT



Tracing 6.1b Orthodromic AVRT is induced by an atrial extrastimulus. The key element of induction of tachycardia is block in the accessory pathway with loss of pre-excitation (*), allowing retrograde conduction up the accessory pathway to the atrium, thereby completing the circuit (see Section 5.4).

AT



Tracing 6.1c In this example, the onset of atrial tachycardia is accompanied by a trivial increase in the AH interval, related to the increased atrial rate. However, subtle changes occur in the P-wave morphology between sinus rhythm (P) and tachycardia (P'), which correspond to slight changes in the atrial activation sequence seen on the intracardiac recordings. The observed AH interval makes AV reentry and AV node reentry very unlikely, since these are almost always associated with obvious AH prolongation.

Case Study

- 74 year old female with a long standing history of palpitations since 1999
- More frequent over the last one year
- In the past, episodes were resolved with Valsalva but now they are not terminated with Valsalva
- Labs, Echo normal

Normal ECG

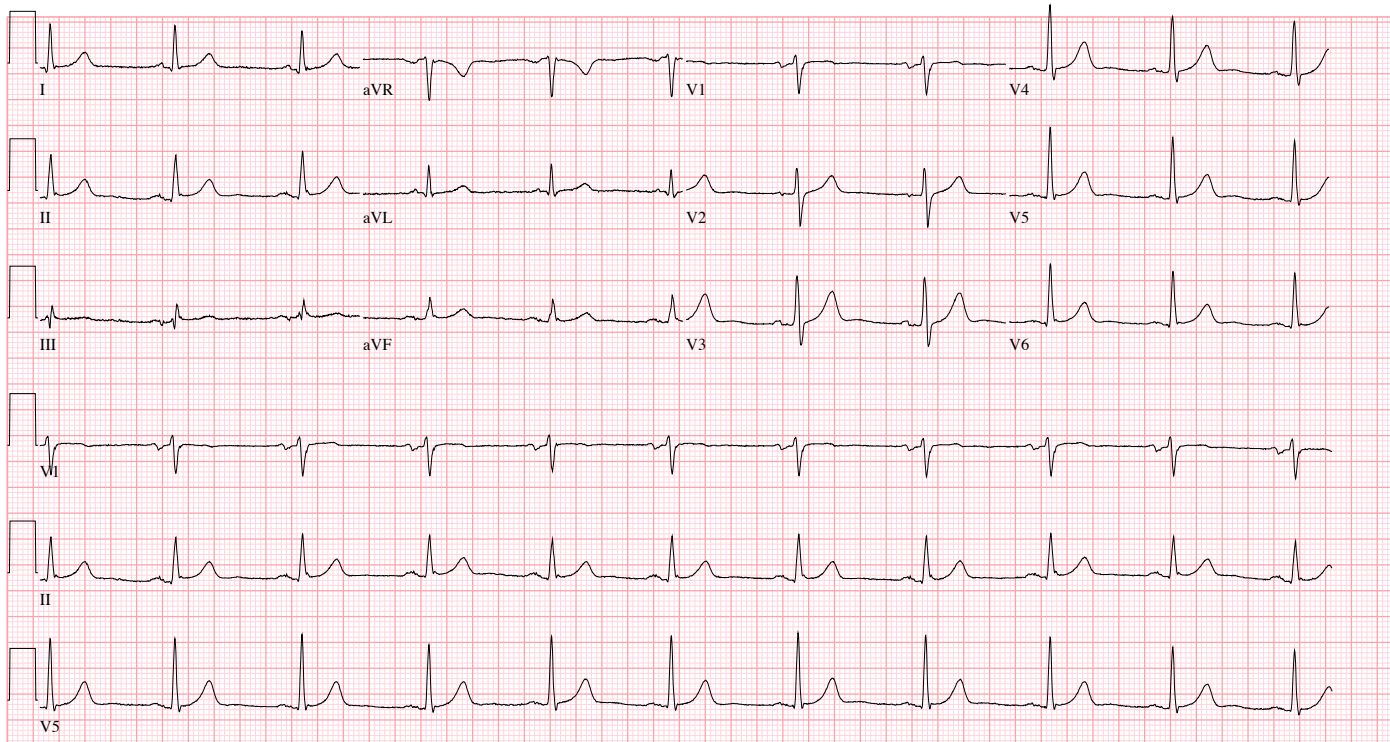
UNIVERSITY HEALTH CARE

Vent. rate	62	BPM
PR interval	154	ms
QRS duration	92	ms
QT/QTc	402/408	ms
P-R-T axes	36 38 40	

Technician: AMBER
Test ind:780.2

Referred by: MOHAMED HAMDAN

Confirmed By: Ravi Ranjan



Baseline

