

## 4D Modeling of Infant Brain Growth in Down's Syndrome and Controls from longitudinal MRI

Clement Vachet<sup>1</sup>, Heather C. Hazlett<sup>2,3</sup>, Joseph Piven<sup>2,3</sup>, and Guido Gerig<sup>1</sup>

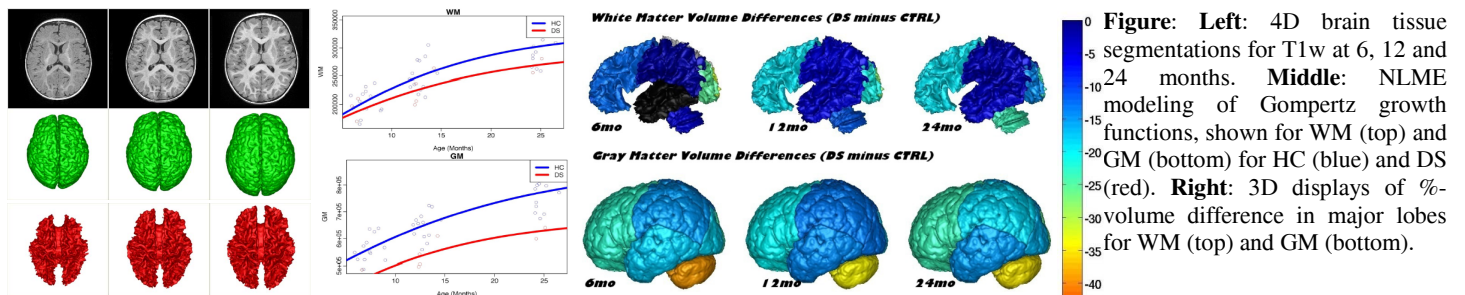
<sup>1</sup>Scientific Computing and Imaging Institute, University of Utah, Salt Lake City, UT, United States, <sup>2</sup>Carolina Institute for Developmental Disabilities, University of North Carolina at Chapel Hill, NC, United States, <sup>3</sup>Department of Psychiatry, University of North Carolina at Chapel Hill, NC, United States

**Introduction:** Modeling of early brain growth trajectories from longitudinal MRI will provide new insight into neurodevelopmental characteristics, timing and type of changes in neurological disorders from controls. In addition to an ongoing large-scale infant autism neuroimaging study<sup>1</sup>, we recruited 4 infants with Down's syndrome (DS) in order to evaluate newly developed methods for 4D segmentation from longitudinal infant MRI, and for temporal modeling of brain growth trajectories. Specifically to Down's, a comparison of patterns of full brain and lobar tissue growth may lead to better insight into the observed variability of cognitive development and neurological effects, and may help with development of disease-modifying therapeutic intervention.

**Materials and Methods:** Healthy control (HC) subjects are part of an ongoing multi-center infant autism study (ACE-IBIS<sup>1</sup>). We randomly selected 13 subjects with three imaging time-points at 6, 12 and 24 months of age. 3D T1 MPRAGE (TR=2400ms, TE=3.16ms) and 3D T2 FSE (TR=3200ms, TE=499ms) with isotropic 1x1x1mm<sup>3</sup> voxel resolution were obtained. 4 subjects with Down's syndrome (DS) were scanned with the same imaging protocols (UNC IRB approved). Due to scheduling conflicts and subject motion, the dataset was incomplete (2 subjects with all three time-points, one subject with only 6- and 12-month scans, and one with only a scan at 12 months).

Brain tissue segmentation was performed for the dual-channel T1w/T2w MRI scans using a joint registration/segmentation concept of 4D image segmentation (3D, time) modified from<sup>2</sup>. In principle, probabilistic tissue segmentation maps from the latest time-point with best tissue contrast replace the common use of external templates for atlas-moderated segmentation, resulting in more consistent subject-specific segmentation maps<sup>3</sup>. Lobar parcellation is obtained by deformable mapping of a two-year-old pediatric atlas to the latest time-point, and then propagated to earlier time-point images via diffeomorphic inter-time-point mappings. Temporal profiles of global and lobe-specific volumes were analyzed by choosing a Gompertz growth function (with intuitive parameters such as delay, rate of change, and expected asymptotic value), nonlinear mixed effect modeling (NLME) and hypothesis testing<sup>4</sup>. NLME naturally accounts for missing data and estimates average (fixed effect) and individual subject-specific growth trajectories (random effects). To help clinicians with interpretation of differences, we adopted a color visualization of %-volume differences to the norm, here the average healthy control brain.

**Results:** This was preliminary analysis due to the very small sample size in DS, but meant to demonstrate the methodology and to serve as a proof of concept. NLME group difference testing of growth functions showed significant differences in the asymptotes of GM ( $p < 0.005$ ) and TBV ( $p < 0.01$ ) but not for WM, which is also reflected in the fixed-effect plots for the three measurements (see Figure middle). Independent testing at the time-points 6 / 12 and 24 months showed  $p < 0.01 / 0.02 / 0.02$  for GM and  $p < 0.03 / 0.04 / 0.03$  for TBV, but no significant differences for WM although WM depicts increasing difference with age. 3D color illustrations demonstrate a very large difference in cerebellum, larger differences in GM versus WM, and considerable lobe-to-lobe variations.



**Discussion and Conclusion:** Smaller head and brain sizes are commonly reported features in DS. However, the literature lacks detailed information on the early developmental trajectory in DS, and even more on any measurements of localized gray and white matter volumetric differences from controls. By applying recently developed 4D segmentation and modeling techniques to subject-specific longitudinal MRI scans, we present a scheme for normative modeling of brain growth, for quantitative analysis of differences at arbitrary time-points, and for testing for alterations in tissue growth trajectories. Applied to DS, we demonstrate analysis and comparison of growth trajectories in a way not possible so far when using conventional independent processing of MRI scans.

### References:

1. Hazlett H.C, et al. Brain Volume Findings in Six Month Old Infants at High Familial Risk for Autism. In *AJP*, 2012 Jun;169(6):601-8
2. Shi F, et al. Neonatal brain image segmentation in longitudinal MRI studies. *NeuroImage*, Volume 49, Issue 1, 1 January 2010, Pages 391-400
3. Vardhan A, Prastawa MW, Gouttard S, Piven J, Gerig G. Quantifying regional growth patterns through longitudinal analysis of distances between multimodal MR intensity distributions. In *Proc. of IEEE ISBI 2012*, pp. 1156--1159. 2012.
4. Sadeghi N, Prastawa M, Fletcher P. T, Wolff J, Gilmore J.H, Gerig G. Regional characterization of longitudinal DT-MRI to study white matter maturation of the early developing brain. *NeuroImage* 2013 Mar;68:236-47

<sup>1</sup>This research is part of the ACE-IBIS Network, an NIH funded Autism Center of Excellence project.